


CHHATRAPATI SHAHU MAHARAJ SHIKSHAN SANSTHA'S  
**DENTAL COLLEGE & HOSPITAL,**  
KANCHANWADI, PAITHAN ROAD, AURANGABAD



# JOURNAL OF PERIOXISION



## **OUR INSPIRATION**



**Hon. Shri. Padmakarji Mulay, Hon. Secretary, CSMSS Sanstha**

## MESSAGE FROM THE HON. PRESIDENT



Chhatrapati Shahu Maharaj Shikshan Sanstha is one of the leading educational society in the State of Maharashtra. It has been the vanguard of continuous development in professional education since its inception. A thought that has been enduring in mind when it becomes real; is truly an interesting and exciting experience. The 'Periovision' Journal Issue-I will definitely inspire all of us for a new beginning enlightened with hope, confidence and faith in each other on the road ahead. It will serve to reinforce and allow increased awareness, improved interaction and integration among all of us.

I congratulate all the students and faculty members of Dental College & Hospital for taking initiatives and bringing this noble task in reality.

**Ranjeet P. Mulay**

**Hon. President, CSMSS Sanstha**

## MESSAGE FROM THE HON. TRUSTEE



I am delighted that Chhatrapati Shahu Maharaj Shikshan Sanstha's Dental College & Hospital is bringing out '**Periovision**' Journal. It is extremely elite to see that the print edition of '**Periovision**' Journal Issue-1 is being published. The journal is now going to be indexed and will be an ideal platform for our researchers to publish their studies especially, Post-Graduate students and faculty of Dental College & Hospital. I wish all success for the Endeavour.

**Sameer P. Mulay**

**Hon. Trustee, CSMSS Sanstha**

## **MESSAGE FROM THE ADMINISTRATIVE OFFICER**



Chhatrapati Shahu Maharaj Shikshan Sanstha is established in 1986, and the dental college under this sanstha was established in 1991. This sanstha has come a long way in all these years, enlightening lives of many students, teachers and most important all the patients in need of healthcare. We always motivate and promote various scientific activities including scientific lectures, research oriented programmes as well as publishing scientific journals.

I congratulate and give my best wishes to the Dean, Editorial Members and all Teaching Staff Members of CSMSS Dental College and Hospital for publishing such an informative Journal.

**Dr. Shrikant Deshmukh**

**A. O. CSMSS Sanstha**

## **MESSAGE FROM THE DEAN**



Innovation is the very basic of progress and unless you innovate, you will remain stagnant. This journal has been created with a vision to provide a platform for all the teaching staff as well as students both Under-Graduates and Post-Graduates, to publish their scientific research work and develop enhancement in their academic career.

I congratulate and give best wishes to the 'Periovision' team as well as students and teaching staff for their efforts in publishing this journal.

**Dr. S. C. Bhoyar**

**DEAN, CSMSS Dental College & Hospital**

## **Chief Patrons**

**Honorable Secretary : Hon. Shri Padmakarji Muley**

**Honorable President : Hon. Shri Ranjeet P. Muley**

**Honorable Trustee : Hon. Shri Sameer P. Muley**

## **Editorial Board**

**Editor-in-Chief** Dr. S. C. Bhoyar

**Editorial Members –** Dr. Maya Mhaske

Dr. Nazish Baig

Dr. Sanjay Sarode

**Associate Editors –** Dr. Niraj Chaudhari

Dr. Anup Cholepatil

Dr. Jayant Ambulgekar

**Creative Director -** Dr. Aniruddha Deshpande

**& Layout Design** Dr. Ashok Chatse

**Honorary editorial –** Dr. Jeevan Khatri

Dr. Lata Kale

**board**

Dr. Babita Yashwante

Dr. Jyoti Khedgikar

Dr. Vrunda Kanjalkar

Dr. Sadashiv Daokar

Dr. Suchita Daokar

Dr. Deepak Motwani

Dr. Ankush Boob

Dr. Sonia Sodhi


## **Author Guidelines**

Maximum of **three** authors will be permitted.

Article should be on **Review/ Case report/ Case series**. Abstracts should contain **150 – 200 words**.

Keywords should be **3 to 5**, font size should be **12 Times New Roman**. Spacing should be **double** and Title in **16 font** including **4 – 5 colored images**.

Article should contain **1200-1500 words** & should be in **word document**.



## CSMSS DENTAL COLLEGE & HOSPITAL AURANGABAD.

### JOURNAL OF PERIOVISION

#### Contents

Sr. No.	Title/Authors	Page No.
1.	<b>Role Of Periodontics In Interdisciplinary Approach</b> Dr. Maya Mhaske, Dr. Nazish Baig, Dr. Poonam Kedar .....	1
2.	<b>Chlorhexidine Or Povidone Iodine Mouth Rinse: Which Is Better?</b> Dr. Niraj Chaudhari.....	4
3.	<b>Gingival Depigmentation: A Case Report</b> Dr. Anup R Cholepatil, Dr. Govind Changule.....	7
4.	<b>Management Of Medical Emergencies In The Dental Clinic:</b> Dr. Ashok Chatse, Dr. Neetu Bhoplawad.....	9
5.	<b>Adieu To Tongue Tie: Lingual Frenectomy: A Case Report</b> Dr. Jayant Ambulgekar.....	12
6.	<b>Management of Mandibular Angle and Parasymphyseal Fractures : A Case Report</b> Dr. S.C. Bhoyar, Dr. Deepak Motwani, Dr. Seema Pendharkar, Dr. Rashmi V.Gaikwad.....	15
7.	<b>Autologous Platelet Rich Fibrin And Its Role In Periodontal Regeneration</b> Dr. Supriya C. Bansode, Dr. Sanjay Sarode, Dr. Vivek Rathod, Dr. Maya Mhaske.....	18
8.	<b>Psychosomatic Aspects Of Oral Diseases: A Review</b> Dr. Lata Kale, Dr. Sonia Sodhi, Dr. Mayuri Suryawanshi, Dr. Vishwas Kadam, Dr. Aishwarya Kale, Dr. Ashish Zope. ....	21
9.	<b>Advances In Local Anaesthesia – A New Horizon</b> Dr. Aniruddha Deshpande, Dr. Nikita Kale.....	25

10.	<b>Management of Chronic Maxillary Sinusitis: A Case Report</b> Dr.S.C.Bhojar, Dr. Seema Pendharkar, Dr. Deepak Motwani, Dr. Akanksha Auti.....	30
11.	<b>Lasers In Periodontics: A Review</b> Dr. Vivek Rathod, Dr. Supriya Bansode, Dr. Maya Mhaske.....	34
12.	<b>PERIO-SIM:- Haptics In Periodontics : A Review</b> Dr. Gaurav Thakare, Dr. Niraj Chaudhari.....	37
13.	<b>Photodynamic Therapy</b> Dr. Poonam Kedar, Dr. Shraddha Bhandari, Dr. Maya Mhaske, Dr. Vrunda Kanjalkar .....	40
14.	<b>Ligaplant</b> Dr. Shraddha Bhandari, Dr. Poonam Kedar, Dr. Maya Mhaske.....	44
15.	<b>New Classification Of The Endo-Perio Continuum: A Review</b> Dr. Arshia R Baig, Dr. Sadashiv Daokar.....	48
16.	<b>Surgical &amp; Non Surgical Treatment Of Oral Leukoplakia</b> Dr. Pallavi Ambhore, Dr. Lata Kale, Dr. Rashmi Phadnis.....	50
17.	<b>Oral Health: Mirror Of General Health</b> Dr. Syeda Shadab Farha, Dr. Sonia Sodhi, Dr. Lata Kale, Dr. Vishwas Kadam.....	52
18.	<b>Oral Cancer- A Global Burden!!!</b> Dr. Jyoti S. Khedgikar, Dr. Revati V.Deshmukh.....	56
19.	<b>Oral Premalignant Lesions Induced By Smokeless Tobacco</b> Dr. Pooja B Muley, Dr. Lata Kale, Dr. Sonia Kaur Sodhi, Dr. Vishwas Kadam .....	57

---

# Role Of Periodontics In Interdisciplinary Approach

Dr. Maya Mhaske<sup>1</sup>,

Dr.Nazish Baig<sup>2</sup>,

Dr.Poonam Kedar<sup>3</sup>

<sup>1</sup>Professor & HOD, Dept. of Periodontology.

<sup>2</sup>Professor, Dept. of Prosthodontics.

<sup>3</sup>PG Student, Dept. of Periodontology.

---

## Abstract

Periodontics can not be practiced in isolation as frequently many patients have multiple dental needs or medical health issues requiring management. In addition, pathology may manifest in the periodontal issues, and the onset and progression of periodontitis can be affected by systemic conditions. Interdisciplinary approach involves the interactions and the interrelationship between periodontal diseases and endodontics, prosthodontics, implant dentistry, esthetics, orthodontics. The intention therefore is to show how and why periodontics should be interdisciplinary, as well as benefits of an interdisciplinary approach; in addition, the potential consequences of using a discipline in isolation are discussed.

**Keywords** Periodontics, interdisciplinary approach, esthetics.

Interdisciplinary team: “Group of dental professionals from various specialty disciplines who combine their expertise and resources to provide care.” (Medical Dictionary for the Dental Professions; Farlex 2012) Interdisciplinary dentistry should be given priority as early as possible because of the prime importance of diagnosis. In this fashion, the scope and quality of the diagnosis becomes considerably widened because the clinician becomes acutely aware of the nuances and fine correlations between tooth size, tooth position, gingival levels, occlusal status, and periodontal condition.

Most importantly. The dental practitioners cannot practice in isolation. Today more than ever, with the explosive growth of implant dentistry, esthetic dentistry, and adult orthodontics. They need to merge their own expertise with that of their team of specialists. The mutual interaction between the various members leads to the exploration of various treatment options and formulae and defines prognosis along with treatment expectations<sup>2</sup>.

## PERIODONAL-ORTHODONTIC CONSIDERATION

The most common objectives of an orthodontic treatment are facial and dental aesthetics and the improvement in the masticatory function. There are a continuously increasing number of adult patients who actively seek orthodontic treatment, and it is also an undeniable fact that the incidence of periodontal

disease increases with age. Therefore, the number of patients with periodontal problems that attend orthodontic practices is significantly greater than in the past.

The most common orthodontic problems found in a periodontally compromised patient include proclination of the maxillary anterior teeth, irregular interdental spacing, rotation, overeruption, migration, loss of teeth or traumatic occlusion. These changes in the dentition are a consequence of the diminished support provided by the compromised periodontium, and they can sometimes hinder periodontal treatment by reducing the conditions for good oral hygiene and impairing function and aesthetics of the stomatognathic system. In all the aforementioned clinical situations, orthodontic treatment may contribute significantly to the overall rehabilitation (aesthetic and functional) of the stomatognathic system. This is the reason that all these periodontal conditions have to be co-evaluated by the periodontist and the orthodontist to choose the appropriate orthodontic intervention. This may involve adjunct tooth movement that can facilitate other dental procedures or comprehensive orthodontic treatment to correct a malocclusion. The final treatment plan must be individualized and tailored to meet the needs, objectives and expectations of the patient.

It is important to delineate the relationship between orthodontics and periodontology and the mode that each field can contribute to optimize treatment of



combined orthodontic– periodontal clinical problems<sup>3</sup>.

**Role of periodontist for Perio-Ortho Therapy**

Preorthodontic Osseous Surgery: Preorthodontic osseous surgery includes correction of Osseous Craters, Bony Defects, Furcation defects as the furcation lesion requires special considerations because they are most difficult to maintain & worsens the orthodontic therapy. Early closure of the spaces during orthodontic treatment using PAOO Technique (Periodontally accelerated osteogenic orthodontics) and selective alveolar decortications or corticotomy approach. Significant acceleration in orthodontic tooth movement has been extensively reported following a combination of selective alveolar decortication and bone grafting surgery with the latter being responsible for the increased scope of tooth movement and the long term improvement of the periodontium. . This technique is one of the newer approach surgical techniques developed to reduce the time for orthodontic treatment and great patient acceptance<sup>4</sup>.

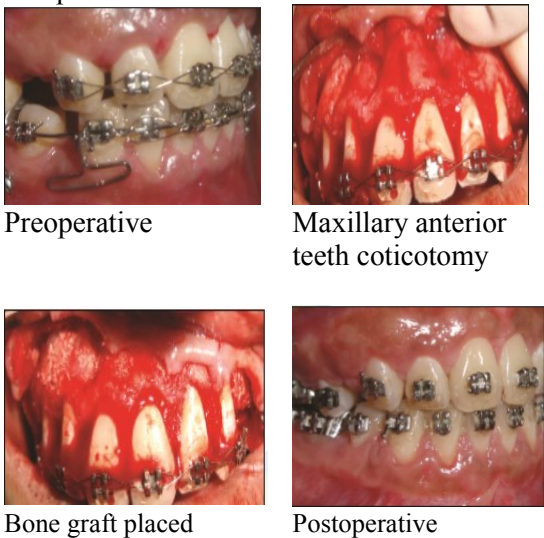


Fig 1. **PAOO TECHNIQUE**

**PERIODONTAL-RESTORATIVE-PROSTHETIC**

The relationship between periodontal health and the restoration of teeth is intimate and inseparable. For restorations to survive long term, the periodontium must remain healthy so that the teeth are maintained. For the periodontium to remain healthy, restorations must be critically managed in several areas so that they are in harmony with their surrounding periodontal tissues. To maintain or enhance the patient's esthetic appearance, the tooth/tissue interface must present a healthy natural appearance, with gingival tissues framing the restored teeth in a

harmonious manner. Close attention to both soft and hard tissues around teeth and implants before, during, and after restorative procedures will greatly increase the probability of a successful outcome.

In the last two decades, the biological and biophysical aspects of fixed reconstructions have received a lot of attention. In addition to careful preparation of the abutment tooth (teeth) designed to receive a crown, biological principles must be considered during the choice of dental materials to be used. If acceptable periodontal conditions are to be achieved and maintained after cementation of a reconstruction, it is important that gingival inflammation or even periodontitis be successfully treated and eliminated before the prosthetic reconstruction is begun<sup>5</sup>.

**Role of Periodontist in Perio-Prosthetic Therapy**

Prosthetic Treatment requires adequate clinical crown exposure so in cases of inadequate crown exposure periodontal treatment like crown lengthening procedure, surgical Crown lengthening needs to be performed. For construction of prosthesis uniform ridges are required for retention & stability so presence of irregular, hyperplastic bulbous ridges requires alveoloplasty.

Deficient vertical ridge height or thickness for the denture or for implant placement requires the ridge augmentation which is done by the periodontist. For successful prosthetic treatment using removable partial denture incorporating clasp for retention and the tooth which serves as an abutment in fixed prosthodontics treatment requires the healthy periodontium to maintain healthy periodontium periodontist has very important role<sup>6</sup>.

**ROLE OF PERIODONTIST IN PERIO-ENDO THERAPY**

The relationship between periodontal and pulpal disease was first described by *Simring and Goldberg* in 1964.

Periodontal inflammation may exert a direct effect on the pulp through the some lateral canal or apical foramen pathways. So Periodontist plays an important role in Preventing the Retrograde Pulpitis .The Treatment of furcation by Periodontal therapy also prevents involvement of accessory canals and thus Prevents endodontic disease.

In cases of endo-perio lesions the correct and complete endodontic treatment will contribute success of regenerative periodontal treatment including correction of the bony defects, furcation involvement by using various platelet concentrates(PRF,PRP),various bone graft materials and GTR membrane<sup>7</sup>.

### PERIO-ESTHETIC CONSIDERATIONS

The gingival complex plays a vital role in the overall beauty of a smile. With the increased emphasis on facial esthetics, both patients and dentists are developing a greater awareness of the impact of the gingiva on the beauty of the smile. So smile enhancement has been brought to the forefront of treatment planning. Role of periodontist associated with esthetics is correction of excessive gingival display (gummy smile), smile designing, correction of black triangles in the esthetic zone by interdental papilla reconstructions by various methods as well as correction of excessive pigmentation of gingiva<sup>8</sup>.

### ROLE OF PERIODONTIST IN IMPLANT CONSIDERATION

Periodontist not only plays a role in successful placement of implant but also plays a role in maintenance by doing scaling and curettage with special equipment and managing the complication associated with implant such as in peri-implantitis<sup>9</sup>. Teamwork is a reality in today's dentistry. Patients demand a higher level of dental care when combining treatments from different clinicians, as they are not only looking for function, but also for esthetics. It is generally accepted today that a clinician cannot always achieve an ideal result by means of conservative dentistry, restorative dentistry, periodontics or orthodontics alone. A high percentage of adult patients show a combination of situations that make an interdisciplinary treatment plan necessary. Interdisciplinary treatments require continuous communication between the different specialists, and understanding the different phases of the treatment is fundamental in order to achieve the desired result. These cases are usually time consuming, and therefore "motivation is key", not only to start the treatment, but also to maintain the complete oral rehabilitation of the patient.

### References

1. Defining Interdisciplinary Studies. 01-Repko-45565.qxd 5/3/2008:3-26.
2. JPH Rogers, PR Stewart, JV Stapleton, DL Hribar, P Adams, AE Gale. An interdisciplinary approach to the management of complex medical and dental conditions. Australian Dental Journal 2000;45:(4):270-276.
3. Jan Lindhe, Clinical Periodontology and Implant Dentistry. 5<sup>th</sup> Edition. Vol 1. Orthodontics and Periodontics. p1241-1275
4. Robert Vanarsdall. Orthodontics and periodontal therapy. Perio 2000 1995;9:132-149
5. Niklaus p. Lang. Periodontal considerations in prosthetic dentistry. Perio 2000 1995; 9: 118-131.
6. Chapter 13. Interdisciplinary considerations; Section 3. Periodontic-Prosthodontic-Restorative Interactions; Ann Periodontol: 230
7. Simring M, Goldberg M. The pulpal pocket approach: retrograde periodontitis. J Periodontol 1964; 35: 22-48.
8. Garber DA, Salama MA. The aesthetic smile and diagnosis. Perio 2000 1996;11:18-28.
9. Tarnow DP, Eskow R N, Zamzok J. Aesthetics and implant dentistry. Perio 2000 1996;11:85-94.

---

# Chlorhexidine Or Povidone Iodine Mouth Rinse: Which Is Better?

Dr. Niraj Chaudhari

Reader, Dept. of Periodontology

---

## Abstract

Antibacterial rinses have many uses in the oral cavity. For antibacterial rinses to be effective in the oral cavity they need to be bactericidal or bacteriostatic and most of all must have a degree of substantivity. Substantivity in a mouthwash is that property that ensures the effect is sustained for a longer period than just the time it is held in the mouth. Based on the evidences available, it is suggested that the use of chlorhexidine mouthwash as antiplaque agent, antiseptic agent, and antibacterial agent over povidone iodine mouthwash would result in significant reduction in bacterial count in saliva there by reducing the oral infections.

**Keywords** Chlorhexidine, Povidone Iodine, Substantivity.

## Introduction

A mouthwash is defined as a medicated solution used for cleaning the oral cavity or treating diseased states of oral tissues. A mouth rinse may be defined simply as a substance that is swished around the oral cavity and then expectorated in order to freshen the mouth and breath. They are often referred to by other names as oral antiseptics and mouth gargles.

The use of mouthwash to control oral bacteria goes back almost 5000 years when the Chinese recommended the use of child's urine for the control of gingivitis.<sup>1</sup>

Antibacterial rinses have many uses in the oral cavity. For antibacterial rinses to be effective in the oral cavity they need to be bactericidal or bacteriostatic and most of all must have a degree of substantivity.<sup>2</sup> Substantivity in a mouthwash is that property that ensures the effect is sustained for a longer period than just the time it is held in the mouth.<sup>3</sup> This is especially important with mouthwashes due to the dilution effect of saliva and fluid intake, which will diminish the effect within minutes if there is no substantivity. There are many types of mouthwashes available in market. But among all these types of mouthwashes the chlorhexidine gluconate mouthwash is the most effective and widely used. Chlorhexidine gluconate (CHX), a bis-biguanide, has been the most widely studied, and has consistently been shown to be the most effective in the management of oral infections.<sup>4-6</sup>

## CHLORHEXIDINE ORAL RINSES

Chlorhexidine is a chemical antiseptic with outstanding bactericidal and bacteriostatic properties. It is well tolerated and has long lasting effects. It has

proved to be the most effective anti-plaque and anti-calculus agent. Chlorhexidine is a chemical antiseptic.<sup>7</sup> It is effective on both Gram-positive and Gram-negative bacteria, although it is less effective with some Gram-negative bacteria.<sup>8</sup> It has both bactericidal and bacteriostatic mechanisms of action, the mechanism of action being membrane disruption, not ATPase inactivation as previously thought.<sup>9</sup> It is also useful against fungi and enveloped viruses, though this has not been extensively investigated. Chlorhexidine is harmful in high concentrations, but is used safely in low concentrations in many products, such as mouthwash and contact lens solutions.

Chlorhexidine digluconate is a widely used agent in periodontitis treatment to prevent the recolonization of bacteria.<sup>10-12</sup> It is available in different formulations such as gels<sup>13</sup>, chips<sup>14</sup>, mouthrinses<sup>11</sup>, and toothbrushes<sup>15</sup>, additives (i.e., fluoride<sup>16</sup>) are supplemented. Because of its bactericidal and bacteriostatic it is widely used to treat various oral and dental related infections.

For decades now, Chlorhexidine (CHX) has been considered a 'gold standard' as an efficient antibacterial and therapeutic oral rinse.<sup>17</sup> The use of this is however not global as a pre-procedural therapeutic rinse.

CHX is primarily used in the treatment of gingivitis, inhibition of dental plaque, as an adjunct to supportive periodontal care, antiseptic oral rinse following dental extractions and surgeries, prevention of alveolar osteitis, treatment of halitosis, and prevention of oral candidiasis.<sup>18-22</sup> CHX 0.2% is the leading antiseptic for controlling gingivitis and plaque inhibition.<sup>23</sup> Although it is a potent antiseptic when used and is known to considerably bring down

the microbial count: it is however, more frequently employed routinely as a postoperative preventive adjunct measure rather than a routine preoperative procedure.<sup>24</sup>

### **Efficacy of Chlorhexidine oral rinses: Evidence based studies**

#### **Antimicrobial activity**

Wide spectrum of activity encompassing gram positive and gram negative bacteria yeasts dermatophytes and some lipophilic viruses. CHX shows different effects at different concentrations. The agent is bacteriostatic whereas at higher concentration the agent is rapidly bactericidal.

#### **Antiplaque activity**

Mechanisms for inhibition of plaque by chlorhexidine.<sup>25</sup>

- The effective blocking of acidic groups of salivary glycoproteins will reduce their adsorption to hydroxyapatite and formation of acquired pellicle.
- The ability of bacteria to bind to tooth surfaces may be reduced by adsorption of CHX to the extracellular polysaccharides of their capsules or glycocalyxes.
- The chlorhexidine may compete with calcium ions for acidic agglutination factors in plaque.

Chlorhexidine is being used as oral rinse since decades and its efficacies are always supported by the studies and clinical trials. CHX is one of the most widely investigated and used oral products.<sup>26</sup>

Antiplaque/antigingivitis effect of chlorhexidine has been supported by the one of the study conducted by Lorenz et al. A clinical trial study was conducted on 90 subjects who were not allowed to use any other oral hygiene measure other than the oral rinse for 14 days. The result showed a significant decrease in plaque regrowth and gingival inflammation than in the placebo group. This study proved that CHX mouth rinses were effective in inhibiting plaque re-growth and gingivitis.<sup>27</sup>

According to the clinical trial conducted on 20 volunteers showed a significant decrease in bacterial count after the use of chlorhexidine mouthwash supporting its bactericidal effects.<sup>28</sup>

This study recommended that it is imperative to use CHX mouth rinse as a recommended 'pre-procedural' standard protocol for all dental related procedures.

### **CHLORHEXIDINE VS POVIDONE IODINE MOUTHWASH**

The studies have proved that the chlorhexidine has longer time of action than the povidone iodine. According to the study conducted by Addy et al on comparison of the in vivo and in vitro antibacterial properties of povidone iodine and chlorhexidine gluconate on 10 subjects, the saliva samples of the subjects post rinsing with the mouthwashes showed that povidone iodine, as a mouthwash, exerts only an immediate antibacterial effect and unlike chlorhexidine, is not retained at antibacterial levels within the oral cavity. This lack of prolonged action of povidone iodine in the oral cavity would appear to be relevant to its reported lack of antiplaque activity.

Chlorhexidine has better healing action when compared to povidone iodine. According to the study conducted by Setiawan.A, Reniart L et al, on comparison of effects of CHX and povidone iodine mouthwash in chemotherapy induced oral mucositis patients of acute lymphoblastic leukemia showed that CHX gave a better result according to rate of healing the patient experience the mucositis and its related pain.

These occur since CHX was absorbed at the tooth surface, plaque and oral mucosa and slowly released in 24 hour period when the saliva concentration decreased. Povidone iodine is not absorbed at tooth surface, plaque and oral mucosa.

The result showed that CHX gave better effect in treating chemotherapy- induced mucositis.

The main disadvantage of povidone iodine mouthwash is regular use is contraindicated in patients or users with thyroid disorders (in particular nodular colloid goiter, endemic goiter and Hashimotos thyroiditis) and in patients with concurrent lithium therapy. Such type of contraindications have not been suggested for chlorhexidine.

### **CONCLUSION**

Chlorhexidine is recognized as gold standard. Although other mouth rinses may show either purely immediate effect or limited persistence, the degree of Chlorhexidine persistence of effect at the tooth surface is the basis of its clinical efficacy. The uniqueness of CHX makes it an effective oral rinse when compared to the other available oral rinses including povidone iodine rinse.

The evidence has showed that the chlorhexidine is the best mouthwash for home care as well as professional usage. Chlorhexidine stands as the most substantiated product for efficacy, safety and an acceptable side effect profile over the povidone iodine mouthwash which has proved to be unadvisable for thyroid patients, patients on lithium therapy. The studies have also proved that the chlorhexidine has better healing action in oral mucositis patients.

Based on the evidences available, it is suggested that the use of chlorhexidine mouthwash as antiplaque agent, antiseptic agent, and antibacterial agent over povidone iodine mouthwash would result in significant reduction in bacterial count in saliva there by reducing the oral infections.

### References

- Mandel ID. Chemotherapeutic agents for controlling plaque and gingivitis. *J Clin Periodontol* 1988;15:488-98
- Grossman E, Meckel AH, Isaacs RL, Ferretti GA, Sturzenberger OP, Bollmer BW, et al. A clinical comparison of antibacterial mouthrinses; effects of chlorhexidine, phenolics, and sanguinarine on dental plaque and gingivitis. *J Periodontol* 1989;60:435-40
- Moran JM Home-use oral hygiene products: mouthrinses. *J Periodontol* 2000;71:482-53.
- Lang NP, Tan WC, Krahenmann MA, Zuhlen M. A systematic review of the effects of full-mouth debridement with and without antiseptics in patients with chronic periodontitis. *J Clin Periodontol* 2008;35:8-21.
- Milstone AM, Passaretti CL, Perl TM. Chlorhexidine: expanding the armamentarium for infection control and prevention. *Clin Infect Dis* 2008;46:274-81.
- Loe H, Schiott CR. The effect of mouthrinses and topical application of chlorhexidine on the development of dental plaque and gingivitis in man. *J Periodontol Res* 1970; 5:79-83.
- "Chlorhexidine" Drugs.com. August 2011. <http://www.drugs.com/pro/chlorhexidine.html>. Retrieved 2011-09-11.
- a b World health organization, Department of Reproductive Health and Research (1998). "The most common topical antimicrobial". Care of the umbilical cord. World Health Organization [http://www.who.int/reproductivehealth/publications/maternal\\_perinatal\\_health/MSM\\_98\\_4/en/](http://www.who.int/reproductivehealth/publications/maternal_perinatal_health/MSM_98_4/en/). Retrieved 2010-09-11.
- Kuyyakanond, T; Quesnel, LB; Selkirk, S; Poole, S (1992). The mechanism of action of chlorhexidine. *FEMS Microbiology letters* 79 (1-3): 211-250. doi:10.1111/i.1574-6968.1991.tb04531.x. PMID 1335944.
- De soete M, Mongardini C, Peuwles M, et al. One stage full mouth disinfection. Long term microbiological results analyzed by checkerboard DNA-DNA hybridization. *J Periodontol* 2001;72:374-382
- Cosyn J, Sabzevar MM. Subgingival chlorhexidine varnish administration as an adjunct to same day full mouth root planning. *J Microbiological observations. J Periodontol* 2007.
- Santos S, Herrera D, Lopez E, O'Connor A, Gonzalez, Sanz M. A Randomized clinical trial on the short term clinical and microbiological effect of the adjunctive use of a 0.05% chlorhexidine mouth rinse for patients in supportive periodontal care. *J Clin Periodontol* 2004.
- Cosyn J, Sabzevar MM. Systematic review on the effects of subgingival chlorhexidine gel administration in the treatment of chronic periodontitis. *J Periodontol* 2005.
- Azma N, Atlla G, Luoto H, Sorsa T. The effect of subgingival controlled released delivery chlorhexidine chip on clinical parameters and matrix metalloproteinase-8 levels in gingival crevicular fluid. *J Periodontol* 2002;73:608-615
- Turner LA, McCombs GB, Hynes WL, Tolle SL. A novel approach to controlling bacterial contamination toothbrushes: chlorhexidine coating. *Int J Dent Hyg* 2009;7:241-245.
- Lorenz K, Bruhn G, Heumann C, Neuschil L, Brex M, Hoffman T. Effect of two new chlorhexidine mouthrinses on the development of dental plaque, gingivitis, and discoloration. Randomized, investigator-blind, placebo-controlled, 3-week experimental gingivitis study. *J Clin Periodontol* 2006;33:561-567.
- Coulter WA, Russel C. Effect of CHX on plaque development in artificial mouth microbias. *J Periodontol* 1979;50:21-8
- Wander Wisden GA, Timmerman M, Novatny GA, Rossema NA, Verkoren AA. Three different rinsing times and inhibition of plaque accumulation with CHX. *JCP* 2014;31:45-51
- Santos S, Herrera D, Lopez E, O'Connor A, Gonzalez I, Sanz M. A RANDOMIZED clinical trial on the short term clinical and microbiological effects of the adjunctive use of a 0.05% CHX mouth rinse for patients in supportive periodontal care. *J Clin Periodontol* 2004;31:45-51
- Barasch A, Safford MM, Dapkute Marqus I, Fine DH. Efficacy of CHX gluconate rinse for treatment and prevention of oral candidiasis in HIV infected children: A pilot study. *Oral Surg Oral Med Oral Pathol Oral Radiol Endod* 2005;99:155-9
- Caso A, Hunk LK, Beirner OR. Prevention of alveolar osteitis with CHX: meta-analytical review. *Oral Surg Oral Med Oral Pathol Oral Radiol Endod* 2005;99:155-9
- Dodd MJ, Larsen PJ, Dibeel SL, et al. Randomized clinical trial of CHX vs placebo for prevention of oral mucositis in patients receiving chemotherapy. *Oncol Nurs Forum* 1996;23:921-7
- Von Strydom DA, Timmerman MF, van der Weijden GA. Plaque inhibition of two commercially available CHX mouthwashes. *JCP* 2005;32:305-9.
- Sreenivasan PK, Gittinus E. The effect of CHX mouthwash on culturable microorganisms of tongue and saliva. *Microbios Res* 2004; 159:365-70.
- CHX – A Gold standard in chemical plaque control. Available at <http://www.edoctor.co.in/dentistry/periodontics/chlorhexidine-a-gold-standard-in-chemical-plaque-control>. Accessed on 12/11/2011
- Joanna Asadoorian. Oral rinsing CDHA position paper on commercially available over the counter oral rinsing product. *Canadian Journal of Dental Hygiene*. July August 2006 VOL.40 NO.4
- Lorenz K, Bruhn G. Effect of two chlorhexidine mouthrinses on development of dental plaque, gingivitis and discoloration. A randomized investigator-blind, placebo controlled, 3 week experimental gingivitis study. *JCP* 2006 AUG;33
- Srinivasan. Efficacy of chlorhexidine mouthwash on oral antiseptics- an in vitro on 20 patients. *Middle East Journal of Family Medicine* Nov 2005 vol 3

---

# Gingival Depigmentation: A Case Report

Dr. Anup R. Cholepatil<sup>1</sup>, Dr. Govind Changule<sup>2</sup>, Dr. Sumedh Lathi<sup>3</sup>

<sup>1</sup>Reader, Dept of Periodontics

<sup>2</sup>Lecturer, Dept of Oral & Maxillofacial Surgery

<sup>3</sup>Reader, Dept. of Conservative Dentistry

---

## Abstract

The gingival tissues play an important role in an esthetically pleasing smile. Smile expresses feelings of joy, success, sensuality, affection, self-confidence, and kindness. The harmony of the smile is determined not only by the shape, position, and color of the teeth but also by the gingival tissues. Melanin pigmentation in the oral cavity is prominent in black individuals. Cosmetic therapy of gingival hyperpigmentation is a common patient request.

**Keywords** Gingival pigmentation, hyperpigmentation, depigmentation.

## Introduction

Melanin, a nonhemoglobin-derived brown pigment, is responsible for the normal pigmentation of the skin, gingiva, and oral mucous membrane. Melanin is present in all normal individuals—often not in sufficient quantities to be detected clinically. Melanin pigmentation in the oral cavity is prominent in black individuals<sup>1</sup>. The colour of gingiva depends on several factors: number and size of blood vessels, thickness of the epithelium, level of keratinization, quantity of pigments. Oral pigmented lesions can have many etiologies, including drugs, heavy metals, genetics, endocrine disturbance, and inflammation<sup>2</sup>. Gingival melanin hyperpigmentation is not a medical problem; however, patients often complain about the unsightly appearance of dark gums. As a result of patients' increasing esthetic demands, clinicians are now expected to provide acceptable gingival esthetics while also addressing any biologic and functional problems. The desire for cosmetic therapy of gingival hyperpigmentation is common among affected patients. Various methods have been used for the treatment of gingival melanin pigmentation, including gingivectomy, gingivectomy with free gingival autografting, acellular dermal matrix allografts, electrosurgery, cryosurgery, abrasion with diamond burs, and various types of laser therapy<sup>3</sup>. This paper describes case report in which gingival depigmentation was carried out.

## Case Report

A 27-year-old female patient reported to the Department of Periodontology, CSMSS Dental

College and Hospital, Aurangabad, India with a chief complaint regarding the black discoloration of her gums. The oral examination revealed pigmented gingiva (fig 1). It was decided to perform depigmentation in a single appointment. The entire procedure was explained to the patient, and written consent was obtained. A complete medical history, family history, and CBC test were performed. Local anesthesia was used in the maxilla and mandible from premolar to premolar. Electrosurgery was used to perform the depigmentation in the first and second quadrant and a diamond bur was used in the third and fourth quadrant (fig 2), periodontal dressing was given. Postsurgical antibiotics (500 mg amoxicillin, three times per day for 5 days) and analgesics (150 mg ibuprofen with 500 mg paracetamol, three times per day for 3 days) were prescribed. The patient was advised to use chlorhexidine mouthwash twice per day for 2 weeks. The patient was evaluated at the end of 1 week and 1 month. At the end of 1 month (fig 3), re-epithelialization was complete, and normal wound healing was evident.

## Discussion

Gingiva has been the most frequently pigmented of the intraoral tissues, in addition to being most readily seen during inspections. Melanin is the fundamental pigment that colours the tissues. It appears as early as three hours after birth in the oral tissues and in some cases is the only sign of pigmentation on the body.<sup>4</sup> Melanin is produced by specialized pigment cells in the gingiva called melanocytes. They are located primarily in the basal layer of the epithelium. Hence,

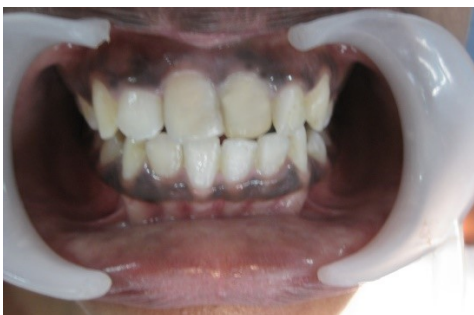it is necessary to remove the entire epithelium. The wound healing takes place by proliferation of cells present along the periphery of the wound. These cells migrate and help in reepithelialization of the wound. Thus, oral repigmentation refers to the clinical reappearance of melanin pigment after a period of clinical depigmentation of the oral mucosa<sup>5</sup>.

Melanocytes have a reproductive self-maintaining system of cells. When locally depleted, they repopulate and keratinocyte-derived growth factors Fibroblast Growth Factor- $\beta$  act as a mitogen. These cells lack desmosomes and possess long dendritic processes that extend between keratinocytes. Melanin is synthesized in the melanocytes in small structures called melanosomes. These melanosomes are injected into the keratinocytes by the dendritic processes. All individuals, whether lightly or darkly pigmented, have the same number of melanocytes in any given region of the mucosa. But, it has been observed that cells with melanin are present in connective tissue in the case of individuals who have a very high melanin pigment. These cells are actually macrophages that have engulfed the melanin pigment<sup>6</sup>.

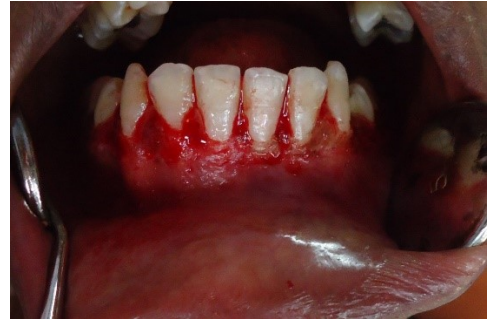Recently, laser ablation has been recognized as one of the most effective, comfortable and reliable techniques for gingival depigmentation<sup>7</sup>. The word laser is an acronym for light amplification by stimulated emission of radiation. Maiman (1960) developed the first working laser.

The success of the depigmentation procedure may be weighed only by the extent of depigmentation achieved and by the time taken for reappearance of pigments, prolonged follow-up is necessary. As the post-operative follow-up of the present study was short, it is proposed that further studies be taken up for a longer period of monitoring along with histopathological assessment to understand the process of repigmentation.

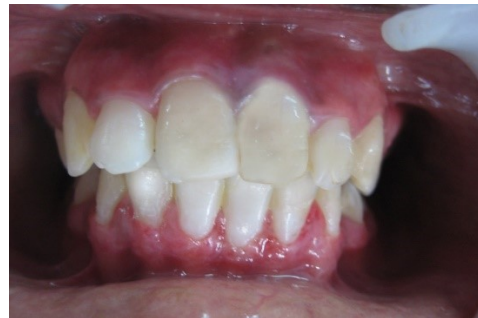## Figures



**FIG 1: PRE OP**



**FIG 2: INTRA OP**



**FIG 3: POST OP**

## References

1. Fiorellini JP, Kim DM, Ishikawa SO. The gingival. In: Newman MG, Takei H, Carranza FA, Klokkevold PR(eds). Carranza's Clinical Periodontology, ed 10. St Louis: Saunders, 2006:46-67.
2. Kuzman A, Pavone M, Blanas N, Bradley G. Pigmented lesions of the oral cavity: review, differential diagnosis, and case presentations. J Can Dent Assoc 2004; 70:682-3.
3. Prasad SSV, Agrawal N, Reddy NR. Gingival depigmentation: A case report. People's J Scientific Res 2010;3:27-30.
4. Farnoosh AA. Treatment of gingival pigmentation and discoloration for esthetic purposes. Int J Periodontics Restorative Dent 1990; 10:312-9.
5. Doshi Y, Khandge N, Byakod G, Patil P. Management of gingival pigmentation with diode laser: Is it a predictive tool? Int J Laser Dent. 2012;2:29-32.
6. Dumett CO, Bolden TE. Post-surgical clinical repigmentation of the gingiva. Oral Surg Oral Med Oral Pathol. 1963;16:353-7.
7. Berk G, Attici K, Berk N. Treatment of gingival pigmentation with Er, Cr: YSGG laser. J Oral Laser Applications. 2005;5:249-53.

---

# Management Of Medical Emergencies In The Dental Clinic:

Dr. Ashok Chatse<sup>1</sup>, Dr. Neetu Bhoplawad<sup>2</sup>

<sup>1</sup>Lecturer, Dept of Periodontology

<sup>2</sup> Lecturer. Dept. Oral and Maxillofacial Surgery

---

## Abstract

Acute medical emergencies can and do occur in the dental office. Preparing for them begins with a team approach by the dentist and staff members who have up-to-date certification in basic life support for health care providers. The ability to react immediately to the emergency at hand, including telephoning for help and having the equipment and drugs needed to respond to an emergency, can mean the difference between successful management and failure.

**Keywords** Blood pressure, cardiac arrest, dental team, coronary heart disease, automated external defibrillator, dental office staff members, drug therapy, medical emergencies, epinephrine Dentists must be prepared to manage medical emergencies which may arise in practice.

## Introduction

**Syncope** is the most common medical emergency seen by dentists.<sup>2,3</sup> Syncope represented approximately 50% of all emergencies, with the next most common event, mild allergy, represented only 8% of all emergencies. In addition to syncope, other emergencies have occurred include allergic reactions, angina pectoris/myocardial infarction, cardiac arrest, postural hypotension, seizures, bronchospasm and diabetic emergencies.

The extent of treatment by the dentist requires preparation, prevention and then management, as necessary. Prevention is accomplished by conducting a thorough medical history with appropriate alterations to dental treatment as required. The most important aspect of nearly all medical emergencies in the dental office is to prevent, or correct, insufficient oxygenation of the brain and heart. Therefore, the management of all medical emergencies should include ensuring that oxygenated blood is being delivered to these critical organs. This is consistent with basic cardiopulmonary resuscitation, with which the dentist must be competent. This provides the skills to manage most medical emergencies, which begin with the assessment, and if necessary the treatment of airway, breathing and circulation (the ABCs of CPR). Usually, only after these ABCs are addressed should the dentist consider the use of emergency drugs.

## I. ESSENTIAL EMERGENCY DRUGS

The following will summarize the drugs which should be part of a dentist's emergency kit. There are 6 drugs which should be considered essential for all dentists.

### 1. Oxygen

Oxygen is indicated for every emergency except hyper-ventilation. This should be done with a clear full face mask for the spontaneously breathing patient and a bag-valve-mask device for the apneic patient. Therefore whenever possible, with the exception of the patient who is hyperventilating, oxygen should be administered.. Short term administration of oxygen to get them through the emergency should not depress their drive to breathe.

Oxygen should be available in a portable source, ideally in an "E"-size cylinder which holds over 600 liters. This should allow for more than enough oxygen to be available for the patient until resolution of the event or transfer to a hospital.

### 2. Epinephrine

Epinephrine is the drug of choice for the emergency treatment of anaphylaxis and asthma which does not respond to its drug of first choice, albuterol or salbutamol. Epinephrine is also indicated for the management of cardiac arrest, but in the dental office setting, it may not be as likely to be given, since intravenous access may not be available..

As a drug, epinephrine has a very rapid onset and short duration of action, usually 5 to 10 minutes when given intravenously. For emergency purposes,



epinephrine is available in two formulations. It is prepared as 1 : 1,000, which equals 1 mg per mL, for intramuscular, including intralingual, injections. More than one ampule or pre-filled syringe should be present as multiple administrations may be necessary. It is also available as 1 : 10,000, which equals 1 mg per 10 mL for intravenous injection. Autoinjector systems are also present for intramuscular use (such as the EpiPen) which provides one dose of 0.3 mg as 0.3 mL of 1 : 1,000, or the pediatric formulation which is 1 dose of 0.15 mg as 0.3 mL of 1 : 2,000. Initial doses for the management of anaphylaxis are 0.3 to 0.5 mg intramuscularly or 0.1 mg intravenously. These doses should be repeated as necessary until resolution of the event. Similar doses should be considered in asthmatic bronchospasm which is unresponsive to a beta-2 agonist, such as albuterol or salbutamol. The dose in cardiac arrest is 1 mg intravenously.

### 3. Nitroglycerin

This drug is indicated for acute angina or myocardial infarction. It is characterized by a rapid onset of action. For emergency purposes it is available as sublingual tablets or a sublingual spray. With signs of angina pectoris, one tablet or spray (0.3 or 0.4 mg) should be administered sublingually. Relief of pain should occur within minutes. If necessary, this dose can be repeated twice more in 5-minute intervals. Systolic blood pressures below 90 mmHg contraindicate the use of this drug.

### 4. Injectable Antihistamine.

Two injectable agents may be considered, either diphenhydramine or chlorpheniramine. They may be administered as part of the management of anaphylaxis or as the sole management of less severe allergic reactions, particularly those with primarily dermatologic signs and symptoms such as urticaria. Recommended doses for adults are 25 to 50 mg of diphenhydramine or 10 to 20 mg of chlorpheniramine.

### 5. Albuterol (Salbutamol)

A selective beta-2 agonist such as albuterol (salbutamol) is the first choice for management of bronchospasm. When administered by means of an inhaler, it provides selective bronchodilation with minimal systemic cardiovascular effects. Adult dose is 2 sprays, to be repeated as necessary. Pediatric dose is 1 spray, repeated as necessary.

### 6. Aspirin

Aspirin (acetylsalicylic acid) is one of the more newly recognized life-saving drugs, as it has been shown to reduce overall mortality from acute myocardial infarction.

The purpose of its administration during an acute myocardial infarction is to prevent the progression from cardiac ischemia to injury to infarction. The lowest effective dose is not known with certainty, but a minimum of 162 mg should be given immediately to any patient with pain suggestive of acute myocardial infarction.

### 7. Oral Carbohydrate

An oral carbohydrate source, such as fruit juice or non-diet soft-drink, should be readily available. Its use is indicated in the management of hypoglycemia in conscious patients.

## II. ADDITIONAL DRUGS

In addition to the 6 drugs discussed above, a number of other drugs should be considered as part of an emergency kit

### 1. Glucagon

The presence of this drug allows intramuscular management of hypoglycemia in an unconscious patient. The ideal management of severe hypoglycemia in a diabetic emergency is the intravenous administration of 50% dextrose. The dose for an adult is 1 mg. If the patient is less than 20 kg, the recommended dose is 0.5 mg

### 2. Atropine

This anti-muscarinic, anti-cholinergic drug is indicated for the management of hypotension, which is accompanied by bradycardia. The dose recommended is 0.5 mg initially, followed by increments as necessary until one reaches a maximum of 3 mg

### 3. Ephedrine

This drug is a vasopressor which may be used to manage significant hypotension. For the treatment of severe hypotension, it is ideally administered in 5 mg increments intravenously. Intramuscularly it should be given in a dose of 10 to 25 mg.

### 4. Corticosteroid

Administration of a corticosteroid such as hydrocortisone may be indicated for the prevention of recurrent anaphylaxis. Hydrocortisone may also play a role in the management of an adrenal crisis. The prototype for this group is hydrocortisone, which may

be administered in a dose of 100 mg as part of the management of these emergencies.

### **5. Morphine**

Morphine is indicated for the management of severe pain which occurs with a myocardial infarction. Advanced Cardiac Life support recommendations list morphine as the analgesic of choice for this purpose.<sup>5</sup>The dose involves titration in one to three mg increments intravenously until pain relief is accomplished.

### **6. Naloxone**

If either morphine is included in the emergency kit, or opioids are used as part of a sedation regimen, then naloxone should also be present for the emergency management of inadvertent overdose. Doses should ideally be titrated slowly in 0.1 mg increments to effect.

### **7. Nitrous Oxide**

Nitrous oxide is a reasonable second choice if morphine is not available to manage pain from a myocardial infarction.

### **8. Injectable Benzodiazepine**

The management of seizures which are prolonged or recurrent, also known as status epilepticus, may require administration of a benzodiazepine. Water-soluble agent such as midazolam or lorazepam. Lorazepam has been reported as the drug of choice

for status epilepticus and can be administered intramuscularly. Adult doses to consider for lorazepam are 4 mg intramuscularly.

### **9. Flumazenil**

The benzodiazepine antagonist flumazenil should be part of the emergency kit when oral or parenteral sedation is used, as these techniques are usually based on effective use of benzodiazepines. Dosage is 0.1 to 0.2 mg intravenously, incrementally.

In addition to having drugs available, a small amount of basic equipment should be readily available. This includes a stethoscope, blood pressure cuff, an oxygen delivery system, syringes and needles.

### **10. Treatment for local anesthetic allergy**

Avoid the problem drug. Treatment varies considerably depending on the symptoms but generally involves supportive measures to ease symptoms: cool showers and topical applications for skin reactions, epinephrine for anaphylactic reactions, antihistamines, steroids, bronchodilator medication.

### **Reference**

1. Matsuura H. Analysis of systemic complications and deaths during dental treatment in Japan. *Anes Prog.* 1989;36:223–225. [PMC free article] [PubMed]
2. Fast TB, Martin MD, Ellis TM. Emergency preparedness: a survey of dental practitioners. *J Am Dent Assoc.* 1986;112:499–501. [PubMed]
3. Malamed SF. *Medical Emergencies in the Dental Office.* 5th ed. St Louis: Mosby; 2000. pp. 58–91.

---

# Adieu To Tongue Tie: Lingual Frenectomy: A Case Report

Dr. Jayant Ambulgekar

Lecturer, Dept of Periodontology

---

## Abstract

A Frenum is a fold of mucous membrane, usually with enclosed muscle fibers, that attaches the lips and cheeks to the alveolar mucosa and/or mucosa and underlying periosteum. Tongue tie or ankyloglossia is a developmental anomaly of the tongue characterized by an abnormally short, thick lingual frenum resulting in limitation of tongue movement. It causes difficulty in speech articulation due to limitation in tongue movement. In this article we report a case of 24 years old female with Tongue tie, complaining of difficulty in speech. It was surgically treated with uneventful healing and good patient satisfaction.

**Keywords** frenum, lingual frenum, ankyloglossia, tongue tie.

## Introduction

Frenum is a fold of mucous membrane, usually with enclosed muscle fibers, that attaches the lips and cheeks to the alveolar mucosa and/or gingiva and underlying periosteum. It is also known as frenulum, frenulums, frenula, or frena. Ankyloglossia, commonly known as tongue tie, is a congenital oral anomaly which may decrease mobility of the tongue tip and is caused by an unusually short, thick lingual frenulum, a membrane connecting the underside of the tongue to the floor of the mouth.<sup>1</sup> Wallace defined tongue-tie as “a condition in which the tip of the tongue cannot be protruded beyond the lower incisor teeth because of a short frenulum linguae, often containing scar tissue.”<sup>2</sup> A lingual frenum attachment limits the tongue's range of motion. The term free-tongue is defined as the length of tongue from the insertion of the lingual frenum into the base of the tongue to the tip of the tongue. Clinically acceptable, normal range of free tongue is greater than 16 mm<sup>3</sup>.

Kotlow Classification of ankyloglossia<sup>3</sup>

- Class I Mild ankyloglossia (12-16 mm)
- Class II Moderate ankyloglossia (8-11 mm)
- Class III Severe ankyloglossia (3-7 mm)
- Class IV Complete ankyloglossia (< 3 mm)

## Case Report

A 24 years old female reported to the Department of Periodontics, with complaint of difficulty in speech and complete protrusion of the tongue. General examination of the patient was normal. Medical history was non-contributory. On intraoral examination the individual was diagnosed with ankyloglossia (tongue tie) and was classified as Class II ankyloglossia by utilizing Kotlow assessment. (Figure 1) She was able to protrude the tongue upto lower lip. There was neither any gingival recession in relation to mandibular incisors lingually nor any malocclusion present. Surgical frenectomy of the lingual frenum was planned. The patient was informed about the treatment procedure and informed consent was obtained.

## Procedure

The procedure was performed under local anesthesia with 2% lignocaine hydrochloride and 1:80,000 adrenaline by using scalpel method. A curved hemostat was inserted to the bottom of the lingual frenum at the depth of the vestibule and clamped into position followed by giving two incisions at the superior and the inferior aspect of the haemostat. Intervening frenum was removed using 11 no. surgical blade and a diamond shape wound was obtained. (Figure 2) Complete dissection was performed by separating the fibers to achieve a good tension free closure of the wound edges. This primary closure of wound minimizes scar formation. Sutures were placed by avoiding adjacent vital structures. Bleeding was minimal and controlled with pressure. The patient was advised to resume normal soft diet as tolerated. To avoid any post-operative

discomfort, antibiotics and analgesics were prescribed for three days. After one week, sutures were removed and good initial healing was observed (Figure 3). The patient was asked to perform tongue exercises for four to six weeks post-operatively following guidance of speech therapist to enhance the tongue mobility and to reduce the potential for scarring. There was significant improvement in speech and gain in tongue protrusion and elevation as compared with pre-operative measures of the tongue mobility. (Figure 4)

### Discussion

Ankyloglossia is a rare congenital oral anomaly that causes difficulty in breast feeding and speech articulation.<sup>3</sup> This anomaly is characterized by the attachment of the tongue to the floor of the mouth. The condition is the result of a failure in cellular degeneration leading to a much longer anchor between the floor of the mouth and the tongue<sup>4</sup>. Ankyloglossia represents a typical interdisciplinary problem concerning different specialties in dentistry. In many individuals ankyloglossia is asymptomatic and may resolve spontaneously. Therefore, surgery for ankyloglossia should be considered at any age depending upon patient's history of speech, mechanical and social difficulty.<sup>5</sup> Surgical techniques for the therapy of tongue-ties can be classified into three procedures. A) Frenotomy is a simple cutting of the frenulum. B) Frenectomy is defined as complete excision, i.e., removal of the whole frenulum. C) Frenuloplasty involves various methods to release the tongue-tie and correct the anatomic situation.

There is no sufficient evidence in the literature concerning surgical treatment options for ankyloglossia to favor any one of the three main techniques.<sup>6</sup> Messner<sup>5</sup> in his study found more than 75 % patients have demonstrable improvements in speech articulation as judged by speech pathologist post-operatively as compared to pre-operatively. Post-operative exercise following tongue-tie surgery were not intended to increase muscle strength, but to: i) Develop new muscle movements, particularly those involving tongue-tip elevation and protrusion, inside and outside of the mouth, ii) Increase kinesthetic awareness of the full range of movements the tongue and lips can perform, iii) Encourage tongue movements related to cleaning the oral cavity, including sweeping the insides of the cheeks, fronts and backs of the teeth, and licking right around both lips.<sup>5,6</sup>

### Conclusion

Ankyloglossia or tongue-tie in most cases is a relatively harmless condition and the treatment is relatively simple effective and safe. In the present case report, lingual frenectomy was done by scalpel technique which provides practical benefit to the patients. There is no enough evidence in the literature to draw any sound conclusion about the timing of surgery for ankyloglossia. Furthermore, no specific surgical method can be favored over others or suggested as the modality of the choice.

Fig. 1

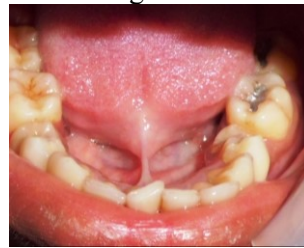


Fig. 2

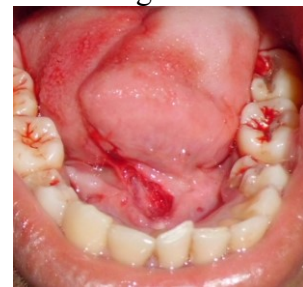


Fig. 3

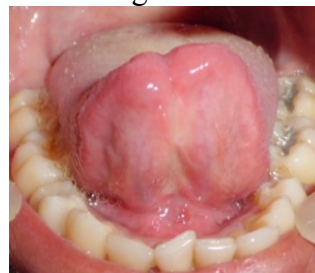
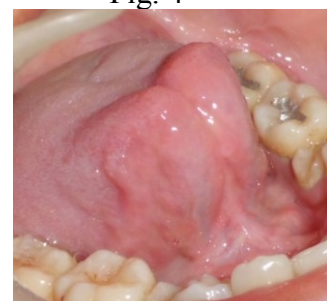
Fig. 4



## References

- 1.Horton CE, Crawford HH, Adamson JE, Ashbell TS. Tongue-tie. *Cleft Palate J* 1969; 6: 8-23. PMID:5251442
- 2.Wallace AF. Tongue tie. *Lancet* 1963; 2: 377-8. [http://dx.doi.org/10.1016/S0140-6736\(63\)93057-5](http://dx.doi.org/10.1016/S0140-6736(63)93057-5)
- 3.Kotlow LA. Ankyloglossia (tongue-tie): A diagnostic and treatment quandary. *Quintessence Intl* 1999; 30: 259-62. PMID:10635253
- 4.Flocken JE. Electrosurgical management of soft tissues and restorative dentistry. *Dent Clin North Am* 1980; 24(2): 247-69. PMID:6928834
- 5.Messner AH, Lalakea ML. The effect of ankyloglossia on speech in children. *Otolaryngol Head Neck Surg* 2002; 127(6): 539-45. <http://dx.doi.org/10.1067/mhn.2002.129731> PMID:12501105
- 6.Chaubal TV, Dixit MB. Ankyloglossia and its management. *J Indian Soc Periodontol* 2011; 15: 270-2. <http://dx.doi.org/10.4103/0972-124X.85673> PMID:22028516 PMCid:PMC3200025
- 7.Suter VG, Bornstein MM. Ankyloglossia: facts and myths in diagnosis and treatment. *J Periodontol* 2009; 80(8): 1204-19. <http://dx.doi.org/10.1902/jop.2009.090086> PMID: 19656020
- 8.Tuli A, Singh A. Monopolar diathermy used for correction of ankyloglossia. *J Indian Soc Pedod Prev Dent* 2010; 28(2): 130-3. <http://dx.doi.org/10.4103/0970-4388.66757> PMID:20660983

---

# Management of Mandibular Angle and Parasymphyseal Fractures : A Case Report

Dr. S.C. Bhoyar<sup>1</sup>; Dr. Deepak Motwani<sup>2</sup>; Dr. Seema Pendharkar<sup>3</sup>; Dr. Rashmi V. Gaikwad<sup>4</sup>

<sup>1</sup>Professor. & HOD Dept. Oral and Maxillofacial Surgery

<sup>2</sup>Professor. Dept. Oral and Maxillofacial Surgery

<sup>3</sup>Sr. Lecturer. Dept. Oral and Maxillofacial Surgery

<sup>4</sup>PG 1<sup>st</sup> MDS Dept. Oral and Maxillofacial Surgery.

---

## Abstract

Fractures of the angle are one of the most common fracture of the mandible. Several technique for treatment of mandibular fracture have evolved significantly in past decade<sup>1</sup>. Over the years, the management of trauma has evolved from various forms of splinting to circum-mandibular wiring, extraoral pins and semirigid fixation with miniplates. Currently used conventional mini plate requires maxillomandibular fixation for a short period and are unable to render 3D stability at the fracture site<sup>2</sup>. A major break through in the field was achieved when Mostafa Farnand (1992) developed a new mini plate system which takes advantage of the bio-geometry to provide stable fixation and he called it a 3D plating system<sup>3</sup>. Shortcomings of rigid and semirigid fixation led to development of 3D miniplates consisting of 2x4 hold miniplates joined by 4 inter connecting cross struts. The 3D plating system are based on principle of obtaining support through geometrically stable configuration.

**Keywords** Angle fractures, Parasymphysis fractures, Mandible, Miniplates.

## Introduction

Fractures of angle and parasymphysis are common fractures of the mandible. The fractures of angle being the most commonest amongst them. Majority of such fractures occur due to interpersonal violence or road traffic accidents. Other potential causes of fractures includes falls, sporting or work related accidents gunshot wounds or pathologic causes may also be included. Fractures occur more frequently in male populations and are most commonly associated with the alcohol consumption. Although most of the fractures occur due to traumatic accidents, but they may occur as a result of pre-existing pathology too. Pathological fractures may result from such conditions such as osteoradionecrosis, bisphosphonates related osteonecrosis, benign tumors malignant tumors large cysts. These kind of pathologies weaken the affected parts of the mandible where fracture occurs with minimal or may there be no trauma. The management of these fractures are controversial. However, the controversy is related to the anatomic relations and complex biomechanical aspects of mandible. The debate has become more heated since, the

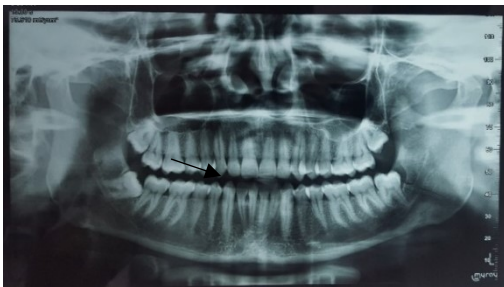evolution of rigid fixation and ability to provide adequate stability of these fractured segments. This article provides an overview of management of the fractured segments by using newer methods of plating system i.e it includes placing 3D miniplates consisting of 2x4 holed miniplates

## Case Report

A 27 year old male patient reported to the department of oral and maxillofacial surgery with the chief complaint of pain during mastication and during opening and closure of the jaw since 7-8 days. Patient was apparently alright with time place and person. Patient gives history of trauma 7-8 days back. He met with a road traffic accident. Clinical examination revealed swelling, ecchymosis and step deformity and tenderness to palpation at inferior border. Intraoral examination reveals ecchymosis gingival laceration and bleeding in posterior buccal and lingual vestibules.

**Radiographic Examination**

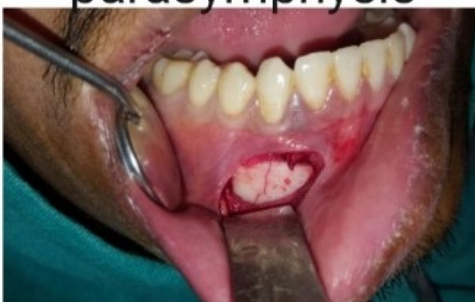This is an OPG of a patient showing parasymphysis fracture line extending between lateral and canine reaching to the border of the mandible , another fracture line is representing the fracture of angle of mandible that extends from distal of the 3<sup>rd</sup> Molar on left side crossing the mandibular canal but not reaching the border



**fig. 1.1 preoperative OPG**

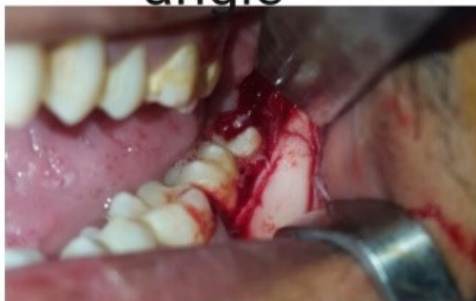**Management :-**

parasymphysis

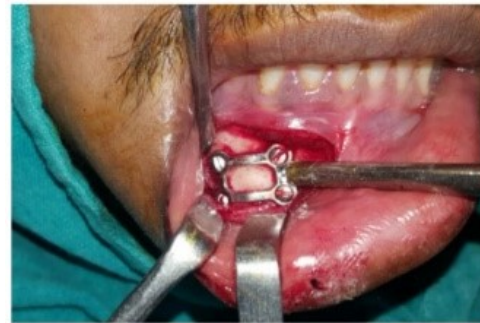

**Fig. 1 a. incision placed**

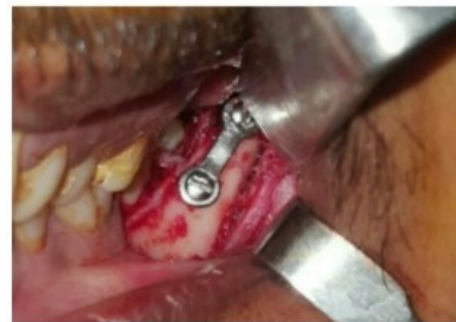angle



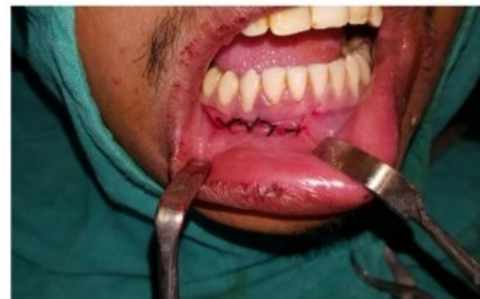**Fig. 2 a. incision placed**



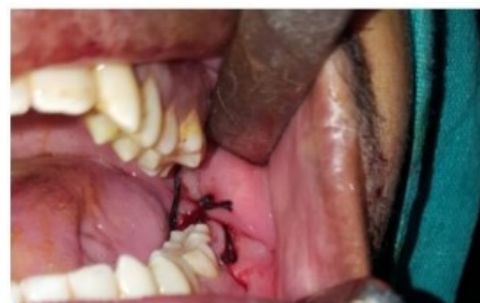**Fig. 1 b. 3DMiniplates placed**



**Fig. 2 b. 2DMiniplates placed**



**Fig. 1 c. Sutures placed**

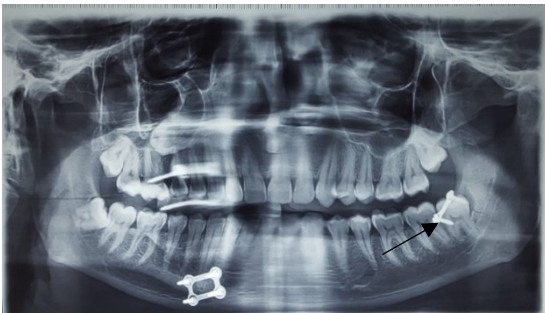

**Fig. 2 c. Sutures placed**

**Fig. 2.1 Intraoperative**

A] Parasymphysisfracture:- A vestibular incision was taken from 42 to 45 . Dissection carried out to achieve sub periosteum and then, the sub periosteum dissection carried till inferior border of the mandible The fracture line was exposed and identified and reduction of the fracture segments was done. Four holed 3x8 mm 3D mini plates were placed across the fracture line and 4 BBSS sutures were placed

B] Angle fracture :- crevicular incision taken distal to 36 along 37 and 38 up to anterior border of ramus of the mandible , dissection performed till sub periosteum , fracture line was then exposed and identified. Fractured segments were reduced two holed miniplates were placed across the fracture line in the buccal cortex and 3 BBSS sutures placed .



**Fig 3.1 Postoperative OPG after reduction of fractured segments and placing 3D Miniplates across the parasymphysis fracture line and 2D miniplates across angle fracture line.**

### Discussion

Most common cause of fracture is a result of road traffic accident accounting for 61.1% . The anatomical distribution of fracture is as follows :- Parasymphysis fractures= 38.8% ,Angle fractures=27.7% ,Symphysis= 11.1% ,Body=11.1%Angle with parasymphysis=11.1%<sup>4</sup> . Mostafa Farnand stated that stable plate osteosynthesis has become an indispensable component of craniomaxillofacial surgery in treatment of the fracture. So compression plate fixations in craniomaxillofacial are nowadays replaced more and more by functionally oriented miniplate system. Ideal miniplates should resist forces depending on the location and be compatible and especially easily adaptable, without dislocation of fragments. These points are influenced by form, size, and material of plates. Mostafa Farnand introduced new 3D plating system in which stability

of the 3D plate is achieved by its configuration , not by thickness on length. These unique plates are composed of linear, square or rectangular units and may theoretically provide increased tensional stability. We typically use these plates for symphysis fractures, which are under a greater degree of torsional strain from other areas of mandible

### References

1. Alysson PO, Abubuara A, Passeri. LA. Analysis of 115 Mandibular angle fractures Journal oral maxillofacial surgery 2008 , 66; 73-6
2. Schmoker R ,Spiessi B excentric dynamic plate. Experimental study as contribution to functionally stable osteosynthesis in mandibular fracture SSO SchweizMonatsschrZankheilkd1973 ; 83(12) 1946-509 (in German)
3. Farnand M 3D plate fixation of fracture and osteotomies: facial plastic surgery. CinNorth Am 1995 ; 3:39-56
4. Fridrich KL , Pena Velasco G , Olson RA changing trends with mandibular fractures . A review of 1,067 cases . Journal Oral Maxillofacial surgery 2005; 63;20914



---

# Autologous Platelet Rich Fibrin And Its Role In Periodontal Regeneration

Dr. Supriya C. Bansode<sup>1</sup>, Dr. Sanjay Sarode<sup>2</sup>, Dr. Vivek Rathod<sup>3</sup>, Dr. Maya Mhaske<sup>4</sup>

<sup>1</sup>PG Student of Periodontology Dept

<sup>2</sup>Associated Professor Dept Of Biochemistry

<sup>3</sup>PG Student Of Periodontology Dept

<sup>4</sup>Hod Of Periodontology Dept

---

## Abstract

Among the great challenges facing clinical research is the development of bioactive surgical additives regulating inflammation and increasing healing. Although the use of fibrin adhesives and platelet-rich plasma (PRP) is well documented, they have their own limitations. Hence, reconstructive dental surgeons are looking for an “edge” that jump starts the healing process to maximize predictability as well as the volume of regenerated bone. Overcoming the restrictions related to the reimplantation of blood derived products, a new family of platelet concentrate, which is neither a fibrin glue nor a classical platelet concentrate, was developed in France.

**Keywords** PRF, Regeneration, Growth factors.

## Introduction

Periodontal disease is defined as a complex, multifactorial disease characterized by the loss of connective tissue attachment with destruction of periodontal tissues. The aim of periodontal therapy is to eliminate inflammatory process, prevent the progression of periodontal disease and also to regenerate the lost periodontal tissues. Periodontal regeneration is a complex multifactorial process involving biologic events like cell adhesion, migration, proliferation, and differentiation in an orchestrated sequence. Periodontal regenerative procedures include soft tissue grafts, bone grafts, root biomodifications, guided tissue regeneration, and combinations of these procedures. The current perspective is that regenerative periodontal therapies to date can only restore a fraction of the original tissue volume and have a limited potential in attaining complete periodontal restoration. Various biomaterials have been used for periodontal tissue regeneration in addition to autogenous and allogenic bone grafts but not a single graft material is considered as gold standard for the treatment of intrabony defects.<sup>1,2</sup>

## PRF

(platelet rich fibrin) was first developed in France for use in the field of oral and maxillofacial surgery. Choukroun's platelet-rich fibrin (PRF) is a leukocyte and platelet rich fibrin biomaterial with a specific

composition and three-dimensional architecture. PRF is classified as a second generation platelet concentrate as it is prepared as a natural concentrate without the addition of any anticoagulants. PRF is often called Choukroun's PRF as there are other platelet concentrates with similar names such as Vivostat PRF (considered a pure platelet-rich plasma) or Fibrinet<sup>3</sup>

## PROTOCOL FOR PREPARATION OF PRF

The classical technique for PRF preparation was invented by Dr. Choukroun in 2000. It is the current PRF technique authorized by the French Health Ministry in which PRF is prepared without using an anticoagulant during blood harvesting or bovine thrombin during gelling. A standard protocol for PRF preparation should be followed to obtain proper quantity and quality of the fibrin matrix, leukocytes, platelets, and growth factors.

The equipment required for PRF preparation includes a

- PC-02 table centrifuge
- blood collection kit consisting of a 24 gauge butterfly needle and 9 ml blood collection tubes.

A sample of blood is collected from patient without anticoagulant in 10 ml tubes which are immediately centrifuged at a rate of 3000 rpm for 10 min. During the centrifugation process, when the blood gets in contact with the test tube wall the platelet gets activated leading to the initiation of coagulation cascade. After centrifugation, the resultant product consists of three layers. The topmost layer consisting of acellular PPP (platelet poor plasma), PRF clot in the middle and RBCs at the bottom of the test tube (see Fig. 1). The fibrin clot obtained after centrifugation is removed from the tube and the attached red blood cells scraped off from it and discarded (see Fig. 2). PRF can also be prepared in the form of a membrane by squeezing out the fluids present in the fibrin clot.<sup>4,5</sup>



Fig. 1



Fig. 2

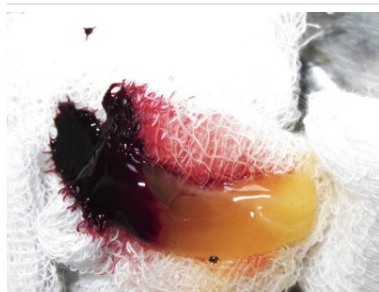


Fig. 3

### POTENTIAL BENEFITS OF USING PRF IN PERIODONTAL REGENERATION

Platelet-rich fibrin is a second generation platelet concentrate which can enhance both soft and hard tissue healing.

Its advantages over platelet-rich plasma include

- Ease of preparation,
- Ease of application
- minimal expense
- lack of biochemical modification (no bovine thrombin or anticoagulant is required).

This considerably reduces the biochemical handling of blood as well as risks associated with the use of

bovine-derived thrombin. PRF also contains physiologically available thrombin that results in slow polymerization of fibrinogen into fibrin which results in a physiologic architecture that is favorable to wound healing.

The cytokines which are present in platelet concentrates play an important role in wound healing. The structural configuration of PRF with respect to cytokine incorporation in fibrin meshes is different from that present in PRP. The natural polymerization in PRF results in increased incorporation of the circulating cytokines in the fibrin meshes (intrinsic cytokines).

Platelets are involved in the process of wound healing by blood clot formation and with regenerative potential via growth factors released from alpha granules. Platelet concentrates are blood extracts after centrifugation for the concentration of growth factors found in platelets. Platelet concentrates can act as bioactive surgical additives that are applied locally to promote wound healing. Platelet-rich plasma is one of the first generation of platelet concentrate techniques with anticoagulants to avoid coagulation during preparation. After two steps of centrifugation, the product requires the addition of bovine thrombin and calcium chloride to achieve artificial clinical polymerization in the natural state. Another added advantage of PRF is the presence of natural fibrin network in PRF which protects the growth factors from proteolysis. PRF also favors the development of microvascularization leading to a more efficient cell migration.<sup>3</sup>

### The $\alpha$ -granules present in platelets contain growth factors like

- Platelet derived factor (PDGF),
- Transforming growth factor- $\beta$  (TGF- $\beta$ ),
- Vascular endothelial growth factor (VEGF),
- Epidermal growth factor (EGF).

Platelet derived growth factor (PDGF) has an important role in periodontal regeneration and wound healing and receptor for PDGF is present on gingiva, periodontal ligament and cementum and it activates fibroblasts and osteoblasts promoting protein synthesis PDGF also functions as a Chang et al. in a study reported that PRF stimulates cell proliferation in a specific manner. PRF induces cell proliferation of osteoblasts, periodontal ligament cells and growth factors during a 3-day culture period and suppressed oral epithelial cell growth. These cell type-specific actions may be beneficial for periodontal regeneration.<sup>6</sup>

### CLINICAL APPLICATIONS

Clinical applications PRF is a powerful healing biomaterial with inherent regenerative capacity and can be used in various procedures such as for the treatment of periodontal

- Intra-bony defects,
- Treatment of furcation,
- Sinus lift procedures
- Scaffold for human periosteal cells in vitro which finds application in the field of tissue engineering.

### DRAWBACKS OF PRF

The main shortcoming of PRF is its preparation and storage. The clinical benefit of PRF depends on time interval between speed of handling between blood collection and centrifugation as PRF is prepared without any addition anticoagulants. Another main disadvantage of PRF is its storage after preparation. Also PRF membranes should be used immediately after preparation as it will shrink resulting in dehydration altering the structural integrity of PRF. Dehydration also results in the decreased growth factor content in PRF and leukocyte viability will be adversely affected altering its biologic properties. PRF when stored in refrigerator can result in risk of bacterial contamination of the membranes. These limitations with the use of PRF can be circumvented by sticking onto a standard protocol for preparation and preservation.

### CONCLUSION

PRF by Choukroun's technique is a simple and inexpensive technique for the successful regeneration of periodontal tissues. The main advantage is that PRF preparation utilizes the patient's own blood reducing or eliminating disease transmission through blood. In the future more studies and clinical trials are needed to investigate potential applications of PRF in the field of periodontal regeneration and tissue engineering and to extend its clinical applications.

### References

1. Platelet-rich fibrin: Its role in periodontal regeneration The Saudi Journal for Dental Research Volume 5, Issue 2, July 2014, Pages 117-122
2. Platelet rich fibrin: a new paradigm in periodontal regeneration September 2013, Volume 14, Issue 3, pp 453-463 .
3. Gau, C.H., Shen, E.C., Tu, H.P. et al. Freezing procedure without thrombin activation to retain and store growth factors from platelet concentrates. J Dent Sci. 2011; 6: 102-106 Choukroun, J., Adda, F., Schoeffer, C., and Vervelle, A. PRF: an opportunity in perio-implantology.
4. . Dohan, D.M., de Peppo, G.M., Doglioli, P., and Sammartino, G. Slow release of growth factors and thrombospondin-1 in Choukroun's platelet-rich fibrin (PRF): a gold standard to achieve for all surgical platelet concentrates technologies. Growth Factors. 2009; 27: 63-6
5. Tsai, C.H., Shen, S.Y., Zhao, J.H., and Chang, Y.C. Platelet-rich fibrin modulates cell proliferation of human periodontally related cells in vitro. J Dent Sci. 2009; 4: 130-135
6. Chang, Y.C. and Zhao, J.H. Effects of platelet-rich fibrin on human periodontal ligament fibroblasts and application for periodontal infra-bony defects. Aust Dent J. 2011; 56: 365-371

---

# Psychosomatic Aspects Of Oral Diseases: A Review

Dr. Lata Kale, Dr. Sonia Sodhi, Dr. Mayuri Suryawanshi, Dr. Vishwas Kadam,  
Dr. Aishwarya Kale, Dr. Ashish Zope.

Department Of Oral Medicine And Radiology.

---

## Abstract

Modern medicine has come to the realization that the human body cannot be treated in terms of a mere sum of its different parts, but must rather be dealt with in terms of the psychophysiological aspects of the organisms as a whole. The mouth is a window to body's health and oral health state can offer lot of clues about the overall health and sometimes the first sign of a disease shows up in mouth. So there is need to learn more about the intimate connection between oral and overall health. A psychosomatic disorder involves both body and mind and these diseases have physical symptoms originating from mental or emotional causes like stress, anxiety and depression.

**Keywords** Psychosomatic, MPDS, lichen planus

## Introduction

There is a rapid upsurge in prevalence rates of psychosomatic disorders in past few decades globally as a consequence of rapidly changing modern life style of people as well as long standing emotion, social and professional stress. It cannot be argued that there are a significant number of patients reporting to the dental office with complaints primarily of psychological origin that affects oral and paraoral structures having definite psychosomatic cause but unfortunately remained unrecognized because of limited nature of their presenting features. Such patients consistently complain of a symptom that he or she interprets as abnormal but dentist can find no convincing physical explanation for the same. Thus this review highlights the significance of increasing psychological factors in society.<sup>[1]</sup>

## HISTORY

Hippocrates (460-377 BCE) the father of clinical medicine, posited four bodily fluids (humors) that, when out of balance, led to various physical maladies. In ancient Greece, Anaxagoras (500-428 BCE) established a distinction between the two. The term "stress" was coined by Selye. The syllable "psych" in "psychosomatic" stems from the ancient Greek term psyche, usually translated as "soul. The ancient Greek root soma, or sōmat, refers to the "body." Another meaning of "psychosomatic" emphasizes the role of the "mind." In the Roman era, the power of the psychological or behavioral domain was explicitly recognized by Cicero, who emphasized personal responsibility for illness (Alexander & Selesnik, 1966). The middle Ages saw a discussion of psychological influences in the writings of St.

Augustine, with his pioneering use of introspection as a psychological tool. In the seventeenth century, Robert Burton's *The Anatomy of Melancholy* recognized psychological elements. In the relatively modern era, i.e. around the turn of the 20th century, further understanding developed of the "inner" workings of the mind, and as a result, methods were developed to study and influence behavior. By this time, organic medicine had developed to a point that physiological mechanisms of psychological influences on bodily function could be appreciated, and the field of psychophysiology was born. An early example is a Cannon's fright-or-flight response mediated by the sympathetic nervous system. Later came Selye's endocrinologically mediated "General Adaptation Syndrome," and most recently an entire new field was established, psychoneuroimmunology, which examines the health impact of communication between the central nervous system and immune systems. Deutsch in 1922 was probably the first author to introduce the term "psychosomatic medicine". Sigmund Freud Systematically studied a case of now famous "Anna O" who was suffering from what then was called hysteria. Explaining the mechanism of psychosomatic disorders, H. Freyberger and R. Sifneos stated that emotional reactions occur in two dimensions: psychological (sensual tons of pleasure or displeasure) and vegetative, which performs an important biological function of energy supply for the coherent behavior. Thus, the study of psychosomatic disorders and psychosomatic diseases has a long history.<sup>[2]</sup>

## RELATIONSHIP BETWEEN “PSCHYE” AND “SOMA”

The relationship between the psyche and soma was explained by two hypotheses:

**Specific hypothesis** :suggests that expression of a predetermined disease or illness occurs due to a specific stimulus or conflicts or stressors. This is due to the heightened response of the body, which persists even after the cessation of stimulus which evoked the change and eventually resulting in a disease.

**Nonspecific hypothesis** :states that generalized stress create preconditions for a number of not necessarily predetermined diseases. According to this hypothesis, four varieties of reactions occur dueto stress viz., healthy normal, neurotic, psychotic, and psychosomatic.<sup>[3],[4]</sup>

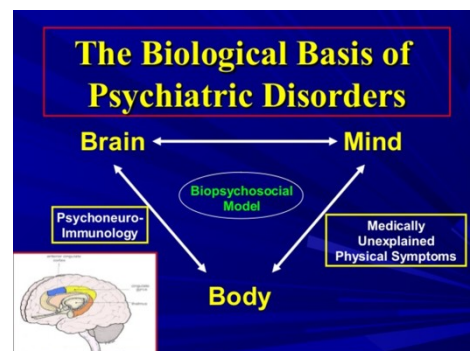
## STRESS AND BODY’S RESPONSE TO STRESS

Life exists by maintaining homeostasis that is constantly confronted by intrinsic and extrinsic forces such as stressors. Favorable conditions enhance the growth, development, and survival of the species. In contrast, activation of the stress response during threatening situations, which are beyond the normal control of an individual, may result in dysphoria and eventually emotional or somatic disease. Stress response activates autonomic nervous system, mainly sympathetic, via hypothalamic–pituitary–adrenal (HPA) axis, which secretes corticotrophin-releasing factor (CRF) and arginine–vasopressin (AVP), leading to release of adrenocorticotrophic hormone (ACTH), enkephalins, and endorphins. Thus, the stress-response function acts by a positive, bidirectional feedback loop. Under no stressful situations, both CRH and AVP are secreted in a circadian, pulsatile manner with approximately 2–3 secretory episodes per hour. In resting conditions, these levels peak in the early morning and gradually decrease as the day progresses. Under stressful situations, these diurnal variations are disrupted. During acute stress, the pulsations of CRH and AVP are enhanced resulting in increased ACTH and cortisol. Various other factors are also released in response to stress, such as angiotensin II, various cytokines, and lipid mediators of inflammation, which act on various components of HPA axis potentiating its activity.<sup>[3],[4]</sup>

## PSYCHOSOMATIC MECHANISMS IN ORAL DISEASES

The term Psychosomatic Dentistry first appeared in print apparently in 1943 in an editorial comment which made a plea for further studies. Early in 1944,

Edward Weiss, M.D.,’ published an article with the title “Psychosomatic Aspects of Dentistry”. Experienced dentists could not observe the destructive effects of clamping and grinding habits without realizing that mechanical stress and strain were but a reflection or consequence of less tangible stress and strain within the personality. A. G. Brodie,” Slilton Leaf, Johnson,R and B. Walker” are outstanding among recent contributors to studies of motor habits and malocclusion in their relation to the personality, while Paul CJ and B. S. Frohman” have made important contributions to the psychotherapy of these sources of oral pathology. Emotional reactions have their origin in quite primitive biologic mechanisms concerned with food getting, with protection from dangers, and with reproduction of the species; in other words, they occur in those organismal reactions most closely related to survival of the individual and of the race-hunger and sex. In humans they become very complex, because in addition to being directly aroused by external threats to life (such as starvation, conquest by enemies, deprivation of affection), they may be activated indirectly by symbols or cues which have come to stand for, or represent, such external situations. Memories, phantasies, the anticipation or misinterpretation of facts can all arouse as strong (and sometimes stronger!) emotional reactions as can actual happenings in the external world. Due to certain neurophysiologic laws, our emotional reactions are established early in childhood and remain as more or less automatic habit patterns throughout life. Often they are hidden or disguised from conscious awareness because, for various reasons, they are unacceptable to a, person’s pride or they clash with accepted social standards. The development of attitudes composing a given personality is a result of the adaptation of inborn biologic strivings to the customs and demands of social living.<sup>[5]</sup>



## OTHER TERMINOLOGIES

Apart from psychosomatics, psychoneuro immunology is a common denotation. Some have called this new field psychoneuro immunoendocrinology to indicate that the endocrine, or hormonal, apparatus is also a part of our system of whole-body response. The DSM Nosology For Psychosomatic Disorders: The concept of psychological medicine, which dates back to the origin of medicine itself, was included in the first edition of “Diagnostic and Statically Manual, Mental Disorder” (DSM-1) in 1952 as “Psychosomatic Disorders” In DSM-II, published in 1968, as Psycho Physiological Autonomic and Visceral Disorder. In 1980” s DSM-III has renamed it has a “Psychological Factor Affecting the Physical Conditions”. To make the category more clinically useful the DSM –IV contains sub categorization format that allows the clinician to specify the type of psychosocial or behavioral factor that affects the patient’s medical condition. The Diagnostic and Statistical Manual of Mental Disorders (DSM), published by the American Psychiatric Association (APA), offers a common language and standard criteria for the classification of mental disorders. The DSM is now in its fifth edition, DSM-5, published on May 18, 2013. Previously, the DSM-IV organized each psychiatric diagnosis into five dimensions (axes) relating to different aspects of disorder or disability:

Axis I: All psychological diagnostic categories except mental retardation and personality disorder

Axis II: Personality disorders and mental retardation

Axis III: General medical condition; acute medical conditions and physical disorders

Axis IV: Psychosocial and environmental factors contributing to the disorder

Axis V: Global Assessment of Functioning or Children's Global Assessment Scale for children and teens under the age of 18.<sup>[2]</sup>

## I. General

### A) According to international classification of diseases (ICD-10;WHO-1993):<sup>[4]</sup>

Psychosomatic disorders are broadly classified depending on whether or not there is tissue damage.

- “Psychological malfunction arising from mental factors:” It describes a variety of physical symptoms or types of psychological malfunctioning of mental origin, not involving tissue damage, and usually mediated through the autonomic nervous system (ANS). For example, respiratory disturbances, such as hyperventilation and psychogenic cough; cardiovascular disturbances, such as cardiac neurosis; and skin disorders such as pruritis.

- Mental disturbances or psychic factors of any type that might have played a major part in the etiology of certain physical conditions usually involving tissue damage. For example, psychogenic conditions, such as asthma, dermatitis, eczema, gastric ulcer, mucous colitis, ulcerative colitis, and urticaria.

### B) According to Zegarelli et al. (1978)<sup>[4]</sup>

- Psychoneurotic disorders
- Psychophysiological disorders
- Personality disorder
- Psychotic disorder.

## II Classification of Psychosomatic Disorders Pertaining to Oral Cavity:<sup>[4]</sup>

According to McCarthy and Shklar (1980)

Oral psychosomatic disease

- Lichen planus
- Apthous stomatitis
- Glossitis and stomatitis areatamigrans

Oral diseases in which psychologic factors may play some etiologic role

- Erythema multiforme
- Mucous membrane pemphigoid
- Chronic periodontal diseases

Oral infections in which emotional stress serves as a predisposing factor

- Recurrent herpes labialis
- Necrotizing gingivitis

Oral diseases induced by neurotic habits

- Leukoplakia
- Biting of oral mucosa (self-mutilation)
- Physical/mechanical irritation
- Dental/periodontal disease produced by bruxism

Neurotic oral symptoms

- Glossodynia (glossopyrosis)
- Dysgeusia
- Mucosal pain.

### B) According to Bailoor and Nagesh (2001)

- Pain-related disorders
  - Myofacial pain dysfunction syndrome
  - Atypical facial pain
- Disorders related to altered oral sensation
  - Burning mouth syndrome
  - Idiopathic xerostomia
  - Idiopathic dysguesia
- Miscellaneous
  - Oral lichen planus
  - Recurrent aphthous ulcers
  - Psoriasis
  - Erythema multiforme
  - Cancerophobia

- f. Acute necrotizing ulcerative gingivitis
- g. Anorexia nervosa
- h. Bruxism

**C) Revised simple working type classification proposed for psychosomatic disorders pertaining to dental practice by Shamim (2014)<sup>[6]</sup>**

1. Pain related disorders:
  - a. Myofascial pain dysfunction syndrome (MPDS)
  - b. Atypical facial pain
  - c. Atypical odontogenic pain
  - d. Phantom pain
2. Disorders related to altered oral sensation:
  - a. Burning mouth syndrome
  - b. Idiopathic xerostomia
  - c. Idiopathic dysgeusia
  - d. Glossodynia
  - e. Glossopyrosis
3. Disorders induced by neurotic habits:
  - a. Dental and periodontal diseases caused by bruxism
  - b. Biting of oral mucosa (self-mutilation)
4. Autoimmune disorders:
  - a. Oral lichen planus
  - b. Recurrent aphthous stomatitis
  - c. Psoriasis
  - d. Mucous membrane pemphigoid
  - e. Erythema multiforme
5. Disorder caused by altered perception of dentofacial form and function:
  - a. Body dysmorphic disorder
6. Miscellaneous disorders:
  - a. Recurrent herpes labialis
  - b. Necrotising ulcerative gingivostomatitis
  - c. Chronic periodontal diseases
  - d. Cancerophobia
  - e. Delusional Halitosis.

**PSYCHOSOMATIC PROBLEMS IN DENTISTRY:**

Medically unexplained oral symptoms (MUOS) Patients who complain of physical symptoms without identifiable etiologies are common in clinical medical practice. Such symptoms are known as medically unexplained symptoms (MUS). The problems of these patients have been called “oral psychosomatic disorders”; but because of the implication that the problem is “psychogenic”, patients are reluctant to

accept the diagnosis. Therefore, the use of another term, “medically unexplained oral symptoms” (MUOS) is preferable. They have reported that the estimated prevalence of MUOS among dental patients ranges from 5 to 10 % or more.

Medically Unexplained Oral symptoms/syndromes (MUOS)<sup>[7]</sup>

1. Burning Mouth Syndrome (BMS) includes dry mouth and dysgeusia
2. Atypical Odontalgia (AO)
3. Oral Cenesthopathy (Oral Dysesthesia)
4. Halitophobia (Olfactory reference syndrome)
5. Occlusal discomfort (Phantom Bite Syndrome)
6. Odontophobia (Dental Phobia)

**MANAGEMENT OF PSYCHOSOMATIC DISORDERS IN DENTISTRY**

Various treatment modalities tried out are:<sup>[4]</sup>

1. Psychotherapy or the remedial influence of mind:
  - a. Cognitive-behavioral therapy
  - b. Self-observation
  - c. Relaxation training
  - d. Hypnotherapy
  - e. Biofeedback
2. Pharmacotherapy
  - a. Antidepressants
  - b. Antianxiety drugs
  - c. Antipsychotic drugs.

**References**

1. Kanodia S et al. Int Arch BioMed Clin Res. 2015;1(1): 3-5.
2. Dhimole et al. BJMMR 2016;14(5);1-9.
3. Suman Sen, Ankit Saha, Tulsi Singh. Effect of Psychosomatic Factors in Oral Diseases. Int J Clin Prev Dent 2014;10(2):51-54
4. Kumar NN, Panchaksharappa MG, Annigeri RG. Psychosomatic disorders: An overview for oral physician. J Indian Acad Oral Med Radiol 2016;28:24-9.
5. Douglas Cordon. PSYCHOSOMATIC MECHANISMS IN ORAL DISEASES.
6. Thorakkal Shamim. The Psychosomatic Disorders Pertaining to Dental Practice with Revised Working Type Classification Korean J Pain. 2014;27(1): 16-22.
7. Akira Toyofuku. Psychosomatic problems in dentistry. BioPsychoSocial Medicine 2016;10;14

---

# Advances In Local Anaesthesia – A New Horizon

Dr. Aniruddha Deshpande<sup>1</sup>, Dr. Nikita Kale<sup>2</sup>

<sup>1</sup>Lecturer, Dept of Periodontics,

<sup>2</sup>Lecturer, Dept of Prosthodontic,

---

## Abstract

Regional nerve blocks provide a practical means of pre-operative and post-operative analgesia for painful oral procedures as an adjunct to general anesthesia. They are technically simple to master, quick and easy to administer and have a low incidence of complications. Few materials are needed to perform regional nerve blocks and many practices may already have the needed supplies. The mental nerve, the inferior alveolar nerve, the infraorbital nerve and the maxillary nerve can be blocked alone or in combination to provide the desired analgesia to any location in the oral cavity. Various modalities have been developed to counter the unwanted anxiety and disadvantages of classical methods of regional nerve block. In addition to the benefits derived from lower anesthetic concentrations, postoperatively these methods of analgesia allows for less aggressive systemic pain management during recovery.

**Keywords** Regional Block, TENS, AMSA, Nano Robots.

## Introduction

Various dental procedures require the use of injected local anaesthesia to make the procedure comfortable for the patient and to facilitate the clinician's ability to provide care. Many patients are apprehensive about receiving local anaesthesia through syringe-needle injection (Malamed 2001)<sup>1</sup>.

**The main drawbacks** associated with it are anxiety, fear of needle, long period of numbness of tissues such as tongue, lips, along with it being painful and uncomfortable to the patient, which cause a reduction in compliance.

## FOLLOWING ARE RECENTLY DEVELOPED METHODS OF ANALGESIA

Recently new novel anesthetic techniques have been developed which includes **transmucosal patch, intrapocket anesthesia, TENS and use of nanorobots** to achieve successful topical anesthesia.

### 1. INTRAPOCKET ANESTHESIA (non – injectable anesthetic gel)

A new **lidocaine/prilocaine intrapocket anesthetic gel (Oraqix®)**<sup>2</sup> has been developed. Oraqix® contains the active ingredients lidocaine and prilocaine base (25 mg/g of each substance), together with thermosetting agents.

It is a low-viscosity fluid, whereas at body temperature it becomes an elastic gel. When applied to a periodontal pocket, it remains at the application site, thereby limiting the risk of its spreading to other areas. It is applied by inserting a 23-G blunt applicator to the bottom of the periodontal pockets before release of the substance. The pockets are filled until the gel became visible at the gingival margin. This method has various advantages such as gets occluded, where it is placed and remains in place at the site. Lidocaine and prilocaine exhibit a biphasic, dose-dependent, vascular response i.e. low concentrations they cause vasoconstriction, and at higher concentrations they cause vasodilation (Covino & Wildsmith 1998), it is easy to apply and its taste does not affect the patients' willingness to have the gel at their next visit.

### 2. ELECTRONIC ANESTHESIA (TENS)

Also known as **transcutaneous electronic nerve stimulation (TENS)**. Fundamental to EA is the gate-control theory of pain proposed by Candido<sup>3</sup>.

**The components** of the system include a TENS control unit, which has dials to control amplitude, wave rate, and width; lead wires with green, black, and blue slide locks; electrode pads; and an injection-assist applicator, 9-V



alkaline or nickel cadmium batteries. Prior to pad placement, the skin where the pads are to be placed must be cleaned with alcohol wipes and dried. Before the pads are placed on the patients, it must be ensured that the control unit is off. For each procedure, there are specific sites for pad placement:

For **mandibular** oral hygiene and periodontal procedures, the pads are placed bilaterally at the mental foramina while, for procedures in the **maxilla**, they are placed bilaterally at the apices of the premolars, just below the zygoma. For the administration of a local anesthetic injection, both the wave rate and wave width are set to maximum (R= 140: W = 250), and the mode switch is set at C (continuous mode). The patient is instructed to turn the amplitude dial until he or she feels a significant sensation. This is maintained for 20 seconds to make sure that the patient is used to the sensation. The amplitude is then increased to the next level, and the cycle is repeated until fasciculation, or quivering, is noted near the pads.

### Indications

- i. Patients who are highly motivated, who strongly object to injections
- ii. Deep scaling & root planing of sensitive roots
- iii. Management of facial pain – myofascial pain, trigeminal neuralgia, TMJ pain

### Contraindications

1. Fearful to electricity,
2. Dislike tingling sensation,
3. Systemic conditions like CVD, pace makers, cerebrovascular d/s, seizures, Pregnancy,
4. Bleeding disorders,
5. Undiagnosed dental pain,
6. Skin lesions & facial abrasions.

### Advantages

1. Noninvasive,
2. Safe,
3. Well accepted by patients,
4. Equipment is easy to operate,
5. Technique is easy to mastered,
6. No risk of allergy,
7. Patient leaves dental office without residual numbness, slurred speech,

### Disadvantages

1. Medical contraindications are still to be strictly observed,
2. Involuntary twitching of the lip and eyelid muscles,
3. Sensation of electricity, which may be unpleasant to some patients, and
4. The inability of EA to achieve profound anesthesia,

However, effectiveness still dependent on psychological variables of patients and the patient management skills of the dentist

### Causes of failure

- Poor case selection
- Lack of communication with the patient and/or poor patient management
- Improper electrode (pad) placement and/or improper equipment setup
- Dirty, oily skin or skin covered with makeup may decrease the effectiveness of EA

Dental electronic anesthesia, although still in its infancy, promises to be an increasingly effective adjunct for the management of dental pain. The technique is noninvasive, safe, and generally well accepted by patients.

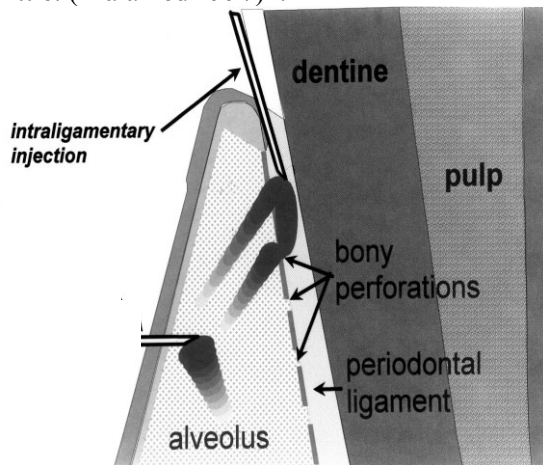
## 3. INTRA-LIGAMENTARY ANAESTHESIA

In the early 1900s, Guido, Fischer, and Cassamani were the first to describe the intraligamentary or periodontal ligament (PDL) local anaesthetic injection technique (1933)<sup>4</sup>. Solution injected via the periodontal ligament reaches the pulpal nerve supply by entering the cancellous bone through natural perforations in the socket wall. Direct administration of a small dose of an analgesic into the periodontal ligament produces elevation of the sensitivity threshold of the periodontium as well as the dental pulp for 10 to 20 min (Walton and Abbott, 1981)<sup>5</sup>.

### Technique

The needle is inserted at 30° to the long axis of the tooth at the mesio-buccal aspect of the root(s). The needle is forced to maximum penetration until it is wedged between the tooth and the crestal bone (Dreyer 1983)<sup>6</sup>. Once the needle is correctly positioned, the solution is injected under back-pressure. The amount of

solution injected into the periodontal ligament is little. (Malamed 1997)<sup>1</sup>.



### Advantages

1. Smaller dose of LA is needed as compared to conventional infiltration and nerve-block anaesthesia (approximately 0.2 mL per root).
2. There is limited spread of anaesthesia in the adjoining soft tissues like lips and cheeks.
3. This technique is advisable in patients with bleeding disorders like haemophilia<sup>7</sup>.

### Disadvantages

1. Intraligamentary injection may produce a bacteremia<sup>8</sup>.
2. Intraligamentary anaesthesia may cause damage to the periodontal tissues. The tissue may show disruption of collagen, lesions over the root surface and alveolar bone. This may be followed by necrosis of the tissues<sup>9</sup>.
3. It may damage the unerupted teeth.
4. Damage to the equipment during deposition of the anaesthetic solution due to excessive pressure upto 5 MPa can occur<sup>10</sup>.

In summary, traditional techniques and technologies used in routine intraligamentary injections are hampered by the blind nature of injection, the extreme pressures generated in local tissue during the procedure, and the relatively small volume of anesthetic that can be reliably delivered.

## 5. COMPUTER-CONTROLLED LOCAL ANESTHETIC DELIVERY SYSTEMS

In 1997, a new concept of drug delivery was introduced to the dental profession: computer-controlled local anesthetic delivery systems (CCLADS) (Hockman, 1997)<sup>11</sup>. The original

CCLADS product was called The Wand and has since been renamed The Wand/Compudent System. This delivery system consists of a computer-controlled drive unit and a separate single-use disposable handpiece/needle assembly. Several other CCLADS followed, including Comfort Control Syringe, QuickSleeper, and Anaject.

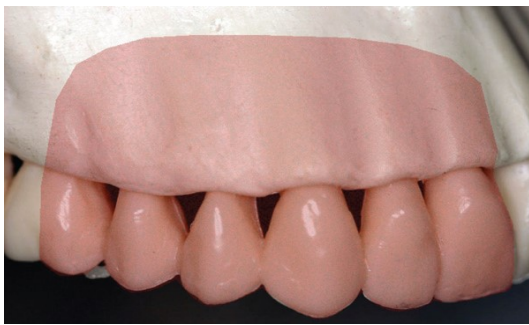In 1998, a fundamental change was introduced to drug delivery systems with the development of dynamic pressure sensing (DPS) technology, which enabled fluid pressure and flow rate at the needle tip to be precisely controlled and monitored during all phases of the injection process (Friedman, 2012)<sup>12</sup>. Applying this new concept to dental injections enables the clinician to perform an easier, faster, and more reliable dental injection technique.

In 2006, a device STA-System: Single tooth anesthesia-system was developed that incorporated DPS technology. Once the needle tip is located in the optimal location, the system provides confirmation (in the form of audible tones, visual display, and spoken alerts) that the needle tip has arrived and has not moved outside the targeted tissue during administration. The recommended dosage of anesthetic solution ranges from 0.9 mL (for single-rooted teeth) to < 1.8 mL (for multi-rooted teeth). The STA-System is comprised of a lightweight, portable drive unit and a separate single-use disposable handpiece assembly attachment (STA-Wand). The drive unit is powered by a standard AC electrical connection. The handpiece consists of a handle, microbore tubing, and an anesthetic cartridge holder that accepts any standard dental anesthetic cartridge and any standard medical needle. The injection is typically performed using 30-gauge or 27-gauge half-inch-lock needle. All injection rates are controlled by the clinician using a foot-control connected to the drive unit.

Thus, the STA-intraligamentary injection provides a unique, single-tooth injection technique that provides a level of safety, comfort, and predictability. The system provides the clinician with multiple benefits that cannot be achieved using the standard dental syringe, the pistol-grip high-pressure syringe.

## 6. ANTERIOR MIDDLE SUPERIOR ALVEOLAR NERVE BLOCK TECHNIQUE (AMSA)

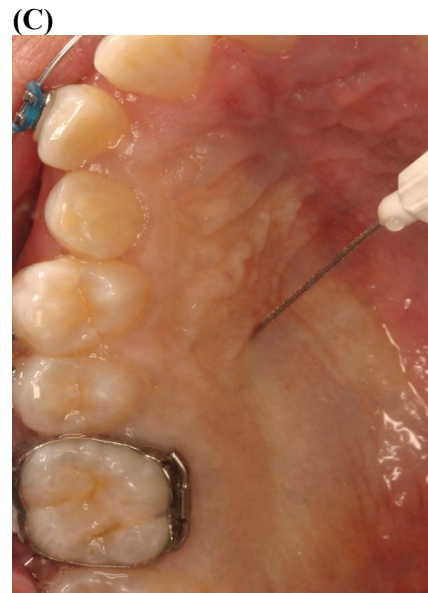
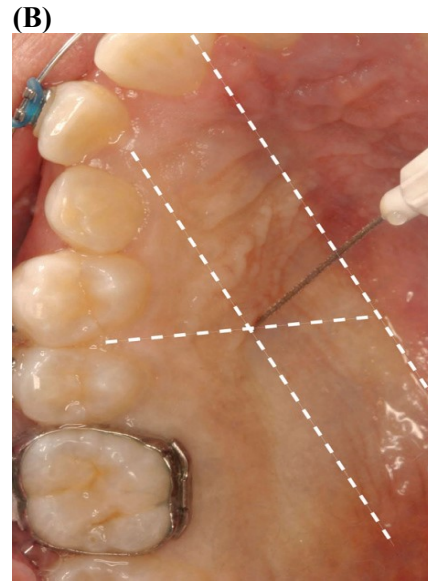
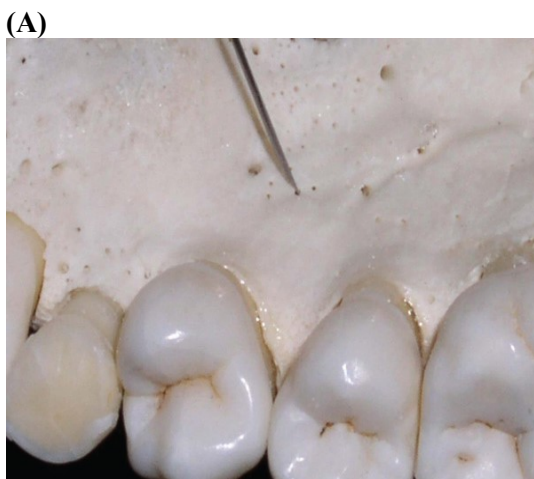Maxillary mucogingival surgery and effective therapeutic periodontal scaling and root planing procedures frequently require the use of local anesthetic to maintain patient comfort while permitting adequate instrumentation. The maxillary arch typically requires up to five injections to obtain anesthesia of the hard and soft tissues. Although this series of injections effectively anesthetizes maxillary tissues, it may also inadvertently affect facial structures, such as the upper lip, lateral aspect of the nose, and lower eyelid.



**Area anaesthetized by AMSA**

To minimize these sequelae and reduce the number of total injections, a relatively new injection technique, the Anterior Middle Superior Alveolar (AMSA) injection technique has been designed (Friedman and Hochman, 2012)<sup>12</sup>. The anterior middle superior alveolar (AMSA) injection is reported to effectively anesthetize maxillary teeth and associated gingival tissues extending from the buccal root of the first molar mesially to the central incisor with a single injection.

### Anatomical location of AMSA



The AMSA injection site is located on the hard palate at the intersection of a vertical line bisecting the premolars and a horizontal line halfway between the midpalatine raphe and the crest of the free gingival margin. To avoid patient discomfort due to the tightly bound nature of the palatal tissue, the anesthetic agent should be injected into the site at a methodic rate of 0.5 ml per minute (Friedman, 2001)<sup>12</sup>. After slow deposition of the anesthetic agent, the bound nature of the palatal tissue promotes diffusion of the anesthetic agent through the palatal bone via numerous nutrient canals. A successful AMSA injection typically blanches the palatal tissue in a unilateral fashion that does not cross the midline. Following diffusion of the anesthetic agent, anesthesia of structures typically innervated by the greater palatine

nerve, nasopalatine nerve, anterior superior alveolar nerve, and middle superior alveolar nerve is achieved.

## 7. USE OF NANOTECHNOLOGY (Nanorobots)

To induce local anesthesia in the era of nanodentistry, a colloidal suspension containing millions of active analgesic micron-size dental nanorobots will be instilled on the patient's gingivae which can crawl through the mucosa, lamina propria or the 1- to 3  $\mu\text{m}$ -thick layer of loose tissue at the cement-dentinal junction. Dentinal tubule diameter increases nearer the pulp, which facilitate nanorobot movements. Assuming a total path length of about 10 mm from the tooth surface to the pulp and a modest travel speed<sup>11</sup> of 100  $\mu\text{m/s}$ , nanorobots can complete the journey into the pulp chamber in approximately **100 seconds**. Once installed in the pulp and having established control over nerve-impulse traffic (Markan S 2017)<sup>13</sup>, the analgesic dental nanorobots may be commanded by the dentist to shut down all sensitivity in any tooth that requires treatment. When the dentist presses the icon for the desired tooth on the hand-held controller display, the selected tooth immediately numbs (or later, on command, awakens). After the oral procedures are completed, the dentist orders the nanorobots (via the same acoustic datalinks) to restore all sensation, to relinquish control of nerve traffic and to egress from the tooth via similar pathways used or ingress; following this, they are aspirated.

### ADV

- greater patient comfort and reduced anxiety,
- no needles,
- greater selectivity and controllability of the analgesic effect,
- fast and completely reversible action, and
- avoidance of most side effects and complications.

The methods described here are useful when conventional techniques fail as all have been shown to increase the incidence of pulpal anaesthesia when used in combination with standard techniques. Knowledge of the various methods is useful as these techniques might be required to provide pain control for

teeth that prove difficult to anaesthetize by the operator's normal route. Although it is in no way intended to replace traditional dental anesthetic methods, these injection techniques may prove useful in certain situations and may add to the clinician's repertoire of anesthetic techniques.

## References

1. Malamed SF. Handbook of Local Anesthesia, 5th ed. St. Louis: Mosby; 2004:213-216.
2. Donaldson D, Gelskey SC, Sandhu HS. A placebo-controlled multi-centred evaluation of an anaesthetic gel (Oraqix<sup>®</sup>) for periodontal therapy. 30 (3); 2003:171–175).
3. Candido KD, Winnie AP, Ghaleb AH, Fattouh MW, Franco CD: Buprenorphine added to the local anesthetic for axillary brachial plexus block prolongs postoperative analgesia. Reg Anesth Pain Med. 27(2); 2002:162-7.
4. Bazin JE, Massoni C, Bruelle P, Fenies V, Groslier D, Schoeffler P: The addition of opioids to local anaesthetics in brachial plexus block: the comparative effects of morphine, buprenorphine and sufentanil. Anaesthesia. 52(9); 1997: 858-62.
5. Walton RE, Abbott BJ. Periodontal ligament injection: a clinical evaluation. J Am Dent Assoc. 1981; 103:571-575.
6. Dreyer WP, van Heerden JD, de V Joubert JJ. The route of periodontal ligament injection of local anesthetic solution. J Endo. 1983; 9: 471-474.
7. Nicholson JW, Berry TG, Summitt JB, et al. Pain perception and utility: a comparison of the syringe and computerized local injection techniques. Gen Dent. 2001;49:167-173.
8. Roberts GJ, Holzel HS, SuryMRJ, Simmons NA, Gardner P, Longhurst P. Dental bacteremia in children. Pediatric Cardiology. 1997: 24(7).
9. BrannstromM, Lindskog S, Nordenvall K-J. Enamel hypoplasia in permanent teeth induced by periodontal ligament anesthesia of primary teeth. Journal of the American Dental Association. 1984;735 (6).
10. Raunak Pradhan, Deepak Kulkarni, and Lakshmi Shetty Evaluation of Efficacy of Intraligamentary Injection Technique for Extraction of Mandibular Teeth-A Prospective Study. J Clin Diagn Res. 2017 Jan; 11(1): 110-13.
11. Hochman M, Chiarello D, Hochman CB, Lopatkin R, Pergola S. Computerized local anesthetic delivery vs. traditional syringe technique: subjective pain response. N Y State Dent J. 1997;63:24-9.
12. Friedman MJ, Hochman MN. Using AMSA and P-ASA nerve blocks for esthetic restorative dentistry. Gen Dent. 2012;49:506-11.
13. Markan S, Lehl G, Kapoor S. Recent Advances of Nanotechnology in Endodontics, Conservative and Preventive Dentistry-A Review. J Dent Oral Biol. 2017; 2(10): 1067

---

# Management of Chronic Maxillary Sinusitis: A Case Report

Dr.S.C.Bhojar<sup>1</sup>, Dr. Seema Pendharkar<sup>2</sup>, Dr. Deepak Motwani<sup>3</sup>, Dr. Akanksha Auti<sup>4</sup>

<sup>1</sup> Dean And HOD, Dept Oral And Maxillofacial Surgery.

<sup>2</sup> Sr. Lecturer, Dept Of Oral And Maxillofacial Surgery.

<sup>3</sup> Professor, Dept Of Oral And Maxillofacial Surgery.

<sup>4</sup> Postgraduate Student, Dept Of Oral And Maxillofacial Surgery.

---

## Abstract

**Introduction** An unnatural communication between the maxillary sinus and oral cavity is known as “oro-antral communication”(OAC) and if it does not close spontaneously, it is epithelized so that oro-antral fistula develops. The most common cause of the oro-antral fistula is the extraction of the maxillary posterior teeth. The close relationship between the apex of these teeth and the thinness of the antral floor explains this. To remove the irreversibly damaged mucosa Caldwell-Luc was designed.

**Objectives** To describe a case report of chronic maxillary sinusitis following oro-antral fistula and its closure

**Case Report** We present a case of 67 years old male patient with right chronic maxillary sinusitis who was designed for Caldwell-Luc procedure to remove the infected sinus lining secondary to maxillary molar extraction

**Conclusion** This treatment modality provide a systematic approach for repair of oro-antral fistula.

**Keywords** Chronic maxillary sinusitis, oro-antral fistula, Caldwell-Luc procedure.

## Introduction

The existence of an unnatural communication between the oral cavity and maxillary sinus due to loss of soft and hard tissues that normally separate these compartments, characterizes the “oro-antral communications”(OAC).<sup>1</sup> The oro-antral fistula(OAF) is a pathological communication between the maxillary sinus and oral cavity and it can be classified as alveolo-sinusal, palatal-sinusal and vestibule-sinusal, depending on the location.<sup>2</sup> Dental infection, radiation therapy, sequelae of removal of maxillary cysts(10-15%) and tumors(5-10%) , osteomyelitis, trauma( 2-5%) can cause OAC.<sup>3</sup>The most common etiologic factor for oroantral communications(OAC) is upper molar extractions (0.31%-4.7%).<sup>4</sup> Oroantral communication (OAC) is the most common complication in the maxilla due to the close proximity of the third molars to the maxillary sinus. The Caldwell-Luc operation was first described as a technique to remove infection and diseased mucosa from the maxillary sinus via the canine fossa.<sup>5</sup>The objective of this article is to describe a case report

of oroantral fistula and its closure by “Caldwell-Luc procedure”.

**Case Report** A 67 year old male patient had referred to the department of the “Oral and maxillofacial surgery”, C.S.M.S.S., Aurangabad with the chief complaint of intraoral drainage in maxillary right quadrant since 5 months. Patient’s history revealed extraction one year back. He also complains of pain over the right maxillary sinus region, runny nose, bad breath and headache. The medical and family histories were non-contributory. Intraoral examination revealed oro-antral communication and liquid drainage through the same. Missing teeth 16, 17,18. Based on history and clinical findings the provisional diagnosis of chronic maxillary sinusitis was given and patient was subjected to radiographic investigations. Radiographic investigations revealed haziness in the right maxillary sinus on OPG, PNS view and CT scan.[Fig. 1] Under all aseptic precautions and local anaesthesia administration (posterior superior alveolar nerve block, infraorbital

block nerve block, greater palatine nerve block) full thickness triangular flap reflected distal to 15 and posteriorly upto 18.[Fig. 2a,2b] Oro-antral communication located buccally in the region of 16 with a probe.[Fig. 2c] Bony window created with postage stamp technique and bony chunk removed.[Fig.2d, 2e] Sinus lavage done with saline and betadine. Closure of flap was done with 3-0 mersilk suture following hemostasis.[Fig.2f] The curetted cystic lining was sent for histopathological examination.[Fig.2g] Patient was recalled after seven days for suture removal. Healing was satisfactory. The patient is on regular follow-up.

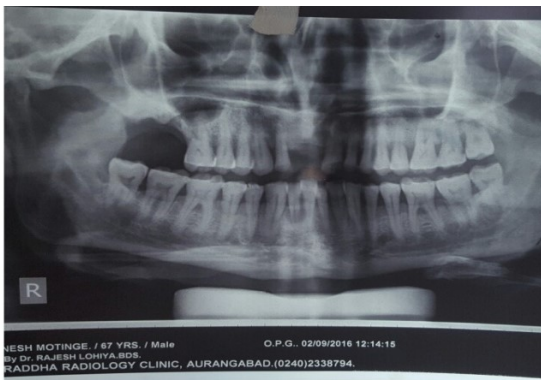

Fig. 1 a - OPG

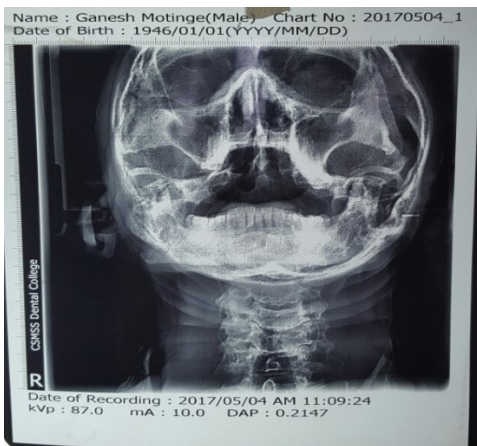

Fig. 1 b PNS view

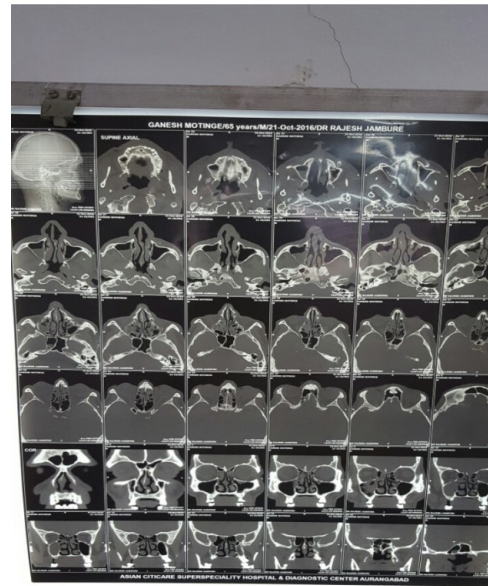

Fig. 1 c – CT Scan

Fig. 1: OPG a; PNS view b; CT scan c.

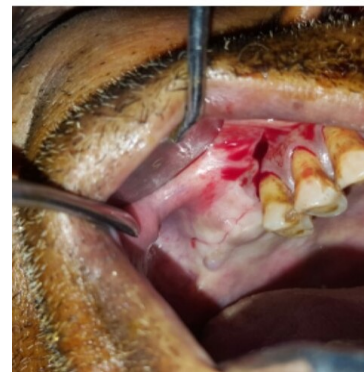

Fig. 2a Incision

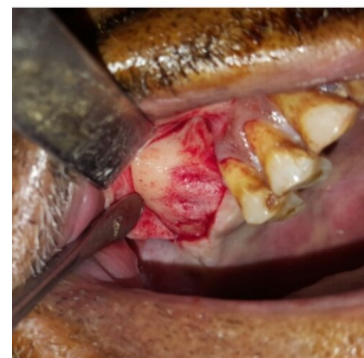

Fig. 2b Full thickness mucoperiosteal flap reflected

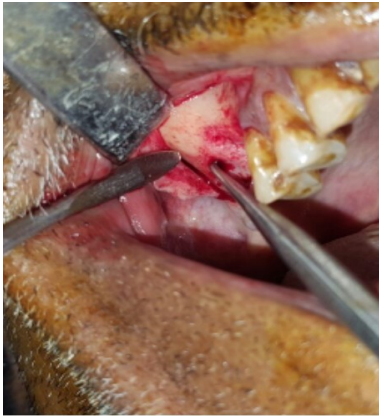

Fig. 2c OAF located

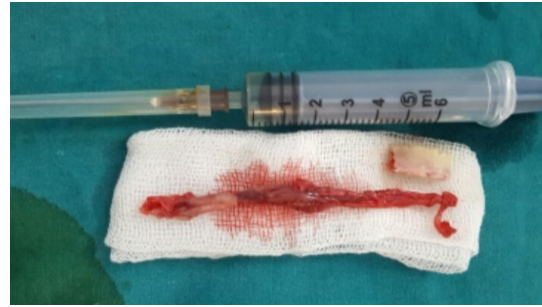

Fig. 2g Infected sinus lining removed

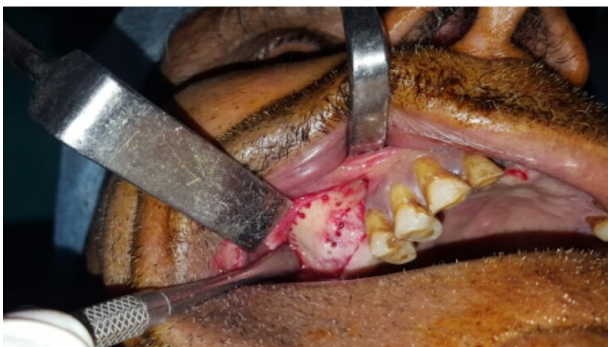

Fig. 2d Postage stamp technique

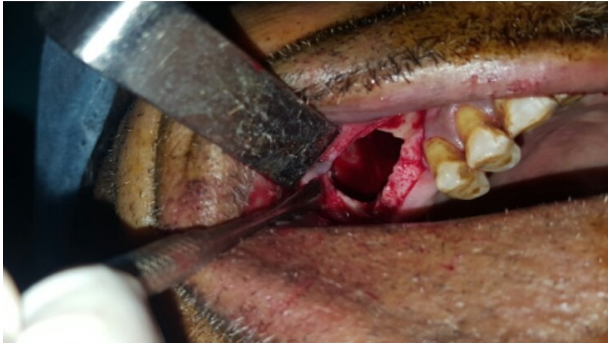

Fig. 2e Bony window created

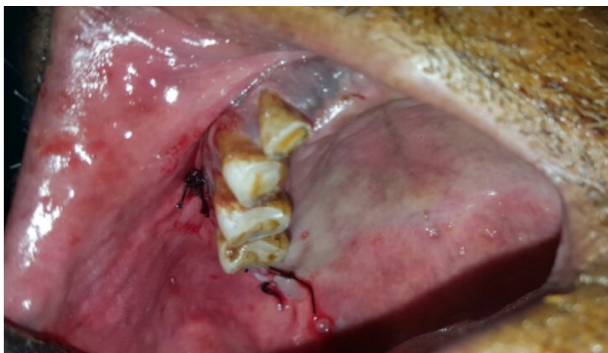


Fig. 2f Wound closure

### Discussion

Maxillary sinus is a part of the paranasal sinuses which is internally revested by a membrane known as “schneiderian membrane”.<sup>6</sup> “Highmore antrum” is the another name of the maxillary sinus.<sup>6</sup> The most important paranasal sinuses are the maxillary sinuses because of their proximity to the roots of maxillary dentition.<sup>7</sup> Inspection of oro-antral communications, especially after maxillary molar and premolar tooth extraction or endodontic surgery performed on maxillary teeth should be done by the surgeon extremely carefully as it can result in sinus perforation which may develop into oroantral communication.<sup>8</sup> The incidence of OAC should be higher after 30 years of life because the maxillary sinus reaches its greatest size during the third decade of life.<sup>3</sup> The incidence rate of 0.31% to 5.1% is there for oroantral communication and subsequent OAF after extraction of upper posterior teeth.<sup>9</sup> OAF occurs after dental extraction. Oroantral fistula is may be the result of several different pathologic processes like infections, inflammatory conditions, neoplasm, Paget’s disease, iatrogenic injury and trauma.<sup>10</sup> Any communication between the oral cavity and the maxillary sinus which lasts for more than 21 days should be closed surgically in order to avoid further medical problems as per the literature.<sup>2</sup> Different parameters must be taken into account including location and size of defect as well as its relationship to the adjacent teeth, height of the alveolar ridge, persistence and sinus inflammation and the patient’s general health while choosing the surgical approach for treatment of an oroantral fistula.<sup>2</sup>

### Conclusion

In this reported case, the “Caldwell-Luc approach” to close the oro-antral fistula proved successful. The operated case had no complications and the oro-antral communication was cured. Patient is under follow up.

## References

1. Marta del Rey Santamaria, Eduard Valmaseda Castellon, Leonardo Berini Aytes, Cosme Gay Escoda. Incidence of oral sinus communications in 389 upper third molar extraction. *Med Oral Patol Oral Cir Bucal* 2006; 11:E334-8.
2. Andrea Enrico Borgonovo, Frederick Valerio Berardinelli, Marco Favale and Carlo Maiorana-Surgical Options in Oroantral Fistula Treatment. *The Open Dentistry Journal*, 2012,6,94-98.
3. Josue Hernando, Lorena Gallego Luis Junquera, Pedro Villarreal. Oroantral Communications. A retrospective analysis. *Med Oral Patol Oral Cir Bucal*. 2010 May 1;15(3):e499-503.
4. Aydin Ozkan, Can Engin Durmaz. Alternative surgical management of oroantral fistula using auricular cartilage. *J Clin Exp Dent*. 2015;7(2):e339-41.
5. Minutha R, Sriram Nathan." A study of Caldwell-Luc approach in various etiologies". *Journal of Evolution of Medical and Dental Sciences* 2013; Vol 2, Issue 36, September 9; page :6715-6723.
6. Pedro Henrique de Souza, Lopes, Diogo de Oliveira Sampaio, and Belmino Carlos Amaral Torres. Combined Palatal flap and titanium mesh for oroantral fistula closure. *Ann Maxillofac Surg*. 2015 Jan-Jun;5(1):89-92.
7. Fahimeh Akhlaghi, Mohammad Esmaeelinejad, and Pooria Safai. Etiologies and Treatments of Odontogenic Maxillary Sinusitis: A Systematic Review. *Iran Red Crescent Med J*. 2015 December; 17(12):e25536.
8. Yunus Feyyat Sahin, Togay Muderris, Sami Bercin, Ergun Sevil, Muzaffer Kiris. Chronic Maxillary Sinusitis Associated with an unusual Foreign Body: A Case Report. *Case Reports in Otolaryngology*. Volume 2012, Article ID 903714, 4 pages.
9. Wael Mohamed Said Ahmed. Closure of Oroantral Fistula Using Titanium Plate with Transalveolar Wiring. *J. Maxillofac. Oral Surg*. (Jan-Mar 2015)14(1):121-125.
10. James J Abrahams, Scott B. Berger. Oral-Maxillary Sinus Fistula (Oroantral fistula): Clinical Features and Findings on Multiplanar CT. *AJR* 1995;165:1273-127



---

# Lasers In Periodontics: A Review

Dr. Vivek Rathod<sup>1</sup>, Dr. Supriya Bansode<sup>2</sup>, Dr. Maya Mhaske<sup>3</sup>

<sup>1</sup>PG Student Dept Of Periodontology

<sup>2</sup>PG Student Dept Of Periodontology

<sup>3</sup>HOD, Professor Dept Of Periodontology

---

## Abstract

Lasers were introduced into the field of clinical dentistry with the hope of overcoming some of the drawbacks posed by the conventional methods of dental procedures. Since its first experiment for dental application in the 1960s, the use of laser has increased rapidly in the last couple of decades. Lasers have been used in initial periodontal therapy, surgery, and also in implant treatment. Further research is necessary so that laser can become a part of the dental armamentarium. This article gives an insight to laser in Periodontics.

**Keywords** Laser, periodontics, periodontology

## Introduction

Dentistry has changed tremendously over the past decade to the benefit of both the clinician and the patient. One technology that has become increasingly utilized in clinical dentistry is that of the laser.

## Laser is an acronym for Light Amplification by Stimulated Emission of Radiation

Laser is a device that utilizes the natural oscillations of atoms or molecule between energy levels for generating coherent electromagnetic radiation usually in the ultraviolet, visible, or infrared regions of the spectrum. It is a device that produces high intensity of a single wavelength and can be focused into a small spot. Initially introduced as an alternative to the traditional halogen curing light the laser now has become the instrument of choice, in many applications, for both periodontal and restorative care. Because of their many advantages, lasers are indicated for a wide variety of procedures. Presently various laser systems have been used in dentistry. Among them Carbon dioxide (CO<sub>2</sub>), Neodymium-doped: Yttrium-Garnet (Nd:YAG), Semiconductor diode lasers are used for soft tissue treatment. Recently Erbium doped: Yttrium-Aluminium-Garnet (Er:YAG) laser has been used for calculus removal and decontamination of the diseased root surface in periodontal non-surgical, surgical and implant therapy.

In 1917 Einstein published ideas on stimulated emission radiation. Based on Albert Einstein's theory of spontaneous and stimulated emission of radiation, Maiman developed the first laser prototype in 1960 using a crystal of ruby as a medium that emitted a coherent radiation light, when stimulated by energy. In 1961, the first gas and continuously operating laser was described by Javan et al.<sup>4</sup> The application of a laser to dental tissue was reported by Stern and Sognaes<sup>5</sup> and Goldman et al. in 1964, describing the effects of ruby laser on enamel and dentine with a disappointing result. Studies on the use of the neodymium-doped yttrium aluminium garnet (Nd:YAG) laser for caries prevention have been published by Yamamoto and Sato<sup>7</sup> and on the use of carbon dioxide (CO<sub>2</sub>) laser for dental caries treatment by Melcher et al.<sup>8</sup> The first dental lasers approved by the US Food and Drug Administration, namely the CO<sub>2</sub>, the Nd:YAG and the diode lasers were accepted for use only for oral soft tissue procedures in periodontics. In 1997, the Food and Drug Administration cleared the first Er:YAG laser system, then in use for preparing dental cavities, for incisions, excisions, vaporization, ablation and hemostasis of soft and hard tissues in the oral cavity. However, with the recent advances and developments of wide range of laser wavelengths and different delivery systems, researchers suggest that lasers could be applied for the dental treatments including periodontal, restorative and surgical treatments. Currently, numerous laser systems are available. Ophthalmologists began using the ruby laser in the early 1960s and now the CO<sub>2</sub> and the Nd:

YAG(neodymium-doped yttrium aluminum garnet), Er,Cr:YSGG, Diode and Er:YAG lasers are established and most commonly used laser for the surgical procedures.

**Applications in Dentistry**

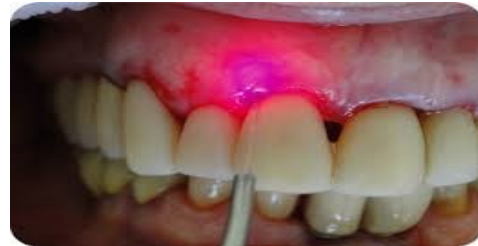- A) Intra oral soft tissue surgery
  - Ablating, incising, excising, coagulating
  - Laser – assisted uvuloplasty
  - Treatment of pathologic condition.
  - Sulcular debridement
  
- B) Hard tissue application
  - Caries removal, inhibition, detection
  - Cavity preparation
  - Surface modification
  - Tooth bleaching
  - Calculus removal
  - Bone ablation and cartilage reshaping
  - Dentin desensitization
  - Analgesia
  
- C) Dental Materials
  - Composite curing, bracket bonding
  - Alloy welding
  - Endodontics
  
- D) Other application
  - Laser diagnostic
  - Instrument sterilization
  - Holography
  - Bio-stimulation

**Applications of Lasers in Periodontal Treatment**

The use of lasers in periodontal treatment has been well documented over the past 10 years. Lasers can be used for initial periodontal therapy and surgical procedures. When used in deep periodontal pockets with associated bony defects, the laser not only removes the diseased granulation tissue and associated bacteria; it also promotes osteoclast and osteoblast activity, often resulting in bone regrowth. This usage becomes more complicated because the periodontium consists of both hard and soft tissues. Among the many lasers available such as CO<sub>2</sub>, Nd:YAG and diode lasers can be used in periodontics because of their excellent ablation and hemostatic characteristics.

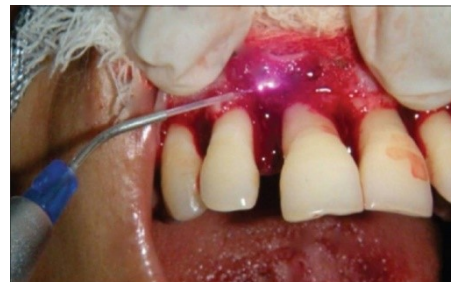**Initial Periodontal Therapy Scaling And Root Planing**

Soft tissue lasers are a good choice in bacterial reduction and coagulation. The erbium group of lasers has shown significant bactericidal effect against porphyromonas gingivalis and actinobacillus actinomycetemcomitans<sup>21</sup>. Reduction of interleukins and pocket depth was noted with laser therapy.



**Soft Tissue Applications**

Laser is effectively used to perform gingivectomies, gingivoplasties, free gingival graft procedures, crown lengthening, operculectomy and many more<sup>22</sup>. Gingival depigmentation using laser ablation has been recognized as-



**LASER ASSISTED NEW ATTACHMENTM PROCEDURE (LANAP)**

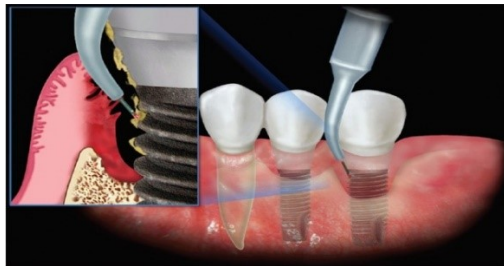
Initial reports suggest that LANAP can be associated with cementum-mediated new connective tissue attachment and apparent periodontal regeneration of diseased root surface in humans.

**Osseous Surgery**

As far as osseous applications, the benefit of the Erbium-YAG is the ability to recontour osseous tissue without the discomfort and healing time commonly seen with traditional methods.

## Laser And Implant

Gingival enlargement is relatively common around implants when they are loaded with removable prosthesis. Lasers can be used for the hyperplasia removal as well as in the treatment for peri-implantitis. Er:YAG laser due to its bactericidal and decontamination effect, can be used in the maintenance of implants. It has bactericidal effect without heat generation around implants<sup>23</sup>. The use of these lasers is limited to gingivectomy, gingivoplasty, frenectomy, deepithelization of reflected periodontal flap, removal of granulation tissue, second stage exposure of dental implants, coagulation of free gingival graft donor sites and gingival depigmentation and metal tattoos of the gingiva. Some researchers have suggested using the Er:YAG Laser to prepare fixture holes in the bone tissue in order to achieve faster osseointegration of the placed implants and to produce less tissue damage in comparison to conventional bur drilling.



## Recent Advances

Waterlase system is a revolutionary dental device that uses laser energized water to cut or ablate soft and hard tissue. Periowave, a photodynamic disinfection system utilizes nontoxic dye (photosensitizer) in combination with low intensity lasers enabling singlet oxygen molecules to destroy bacteria.

As technology advances into dentistry, whether it is laser or another exciting venue, the options available to clinicians will continue to increase.

Although the use of lasers in dentistry is relatively new, the future looks very bright. In summary, laser treatment is expected to serve as an alternative or adjunctive to conventional mechanical periodontal treatment. Currently, among the different types of lasers available, Er:YAG and Er,Cr:YSGG laser possess characteristics suitable for dental treatment, due to its dual ability to ablate soft and hard tissues with minimal damage. In addition, its bactericidal effect with elimination of lipopolysaccharide, ability to remove bacterial plaque and calculus, irradiation effect limited to an ultra-thin layer of tissue, faster bone and soft tissue repair, make it a promising tool for periodontal treatment including scaling and root surface debridement. The decision to use a laser should be based on the proven benefits of hemostasis, a dry and effective, pleasant, and a reliable technique. In terms of aesthetic dentistry, the use of the Erbium laser in crown lengthening in the anterior has created an entirely new field, reduced surgical time and the general experience of less postoperative swelling.

## References

1. Schwarz F, Aoki A, Sculean A, Becker J. The impact of laser application on periodontal and peri-implant wound healing. *Perio 2000* 2009;51:79-108.
2. Walsh LJ. The current status of laser applications in dentistry. *Aust Dent J* 2003; 48:146-55.
3. Charles M. Cobb\*Lasers in Periodontics: A Review of the Literature Volume 77 • Number 4 J Periodontol • April 2006.
4. Role of lasers in periodontology: A Review Aashima B Dang, 1 Neelakshi S Rallan2. *Annals of Dental Specialty* 2013 ; Volume 01 , Issue 011.
5. An Overview of Lasers in Dentistry; ©Academy of Laser Dentistry 2008 Pg 1-18.
6. The Use of a Diode Laser in Periodontics: Lambda Scientifica.
7. AAP-Commissioned Review, Lasers in Periodontics: A Review of the Literature Charles M. Cobb\* J Periodontol 2006;77: 545-564.
8. Kreisler M, Al Haj H, d'Hoedt B: Temperature changes at the implant –bone interface during simulated surface decontamination with an Er:YAG laser, *Int J Prosthodont* 15:582,2002

---

# PERIO-SIM:- Haptics In Periodontics : A Review

Dr. Gaurav Thakare<sup>1</sup>, Dr. Niraj Chaudhari<sup>2</sup>

<sup>1</sup>PG Student, Dept. Of Periodontology

<sup>2</sup>Reader, Dept. Of Periodontology

---

## Abstract

Haptic technology (sense of touch) along with 3D-virtual reality (VR) graphics, creating lifelike training simulations, was used to develop a dental training simulator system (PerioSim). The haptic device employed was a PHANToM and the simulator a Dell Xeon 530 workstation with 3D, VR oral models and instruments viewed on a stereoscopic monitor. An onscreen VR periodontal probe or explorer was manipulated by operating the PHANToM for sensing lifelike contact and interactions with the teeth and gingiva. A PowerPoint presentation on one screen provided instructions for the simulator use with the 3D, VR simulator on a second stereoscopic monitor viewed with 3D goggles. Tactile sensation was realistic for teeth but not so for gingiva. The onscreen instructions were very useful with high potential for teaching. Faculty members anticipated incorporating this device into teaching and were enthusiastic about its potential for evaluating students' basic procedural skills.

**Keywords** PerioSim, Periodontal Stimulator

## Introduction

Dental and medical education has utilized technology increasingly over the past few years for learning as well as training. Medical simulation has become a valuable tool for learning and acquiring skills. Acquiring abilities and skills to perform dental procedures is essential for dental students and clinicians. It takes more than only observing patients, diagnosing and managing the disease but also needs a practical experience of the tactile information to gain surgical expertise. Till date, these are gained in the laboratories of the dental faculties in two stages. Firstly, dental students are trained on artificial teeth, placed within a manikin head, using real dental instruments, like burs, etc., Practicing on manikins reduces the risk to some extent but is less effective considering the cost, availability, and lack of rare real-world cases (cannot provide the level of detail and material properties of real life teeth and procedures). In the second stage, the students perform dental procedures on real patients under the close supervision of their professors. So, the students/clinicians go through a trial and error process by working on real patients before achieving better and more consistent experience and safe performance of dental and medical procedures.

Although the conventional techniques have their own importance in training but to practice on live patients, students/clinicians must know how to use the tools and the material properties of the organs (e.g. before taking up surgeries on real patients, we need to have a feel of soft tissues and bone texture, which is not possible in a conventional setup). Hence, a system, which simulates real dental procedures graphically and haptically, will be a better option to increase students' knowledge/experience level and to perform mock surgeries before they actually practice them on live patients. Hence, introduction of haptic technology can bring about better outcomes with less error. It is a technology of tactile feedback that makes use of a user's sense of touch by applying vibrations, forces or motions to the user

## BACKGROUND AND PRINCIPLES

Haptics-based simulators employ a haptic device and a platform to facilitate dental practicing (virtual models of a human tooth or mouth). The trainee holds the stylus of haptic device instead of real dental instruments and can manipulate the instruments, shown on the screen, which in turn reproduces clinical sensations in the hand of the operator through tactile feedback.

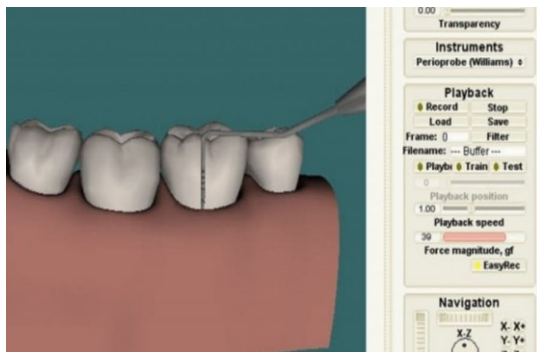
It works on the principles of creating virtual environment, which replaces the reality, and user can interact to perform various motor and perceptual tasks. It can help one to be mentally transported and immersed in virtual worlds through various computer software.

Armamentarium includes:

- Monitor and speakers
- Haptic interface device (stylus)
- Glasses and helmets for visualizing 2D video display as 3D



Simulator Monitor Phantom Haptic Device Instructional Monitor  
Dr AD Steinberg 2008 ©



### Application

Differentiating between pathological and normal conditions, diagnosing and treat periodontal diseases requires skill which can be achieved by employing one of the two visuo-haptic systems: PerioSim and a periodontal simulator.[2,3]

Periosim and periodontal simulator were developed by university of Illinois at Chicago. The application simulates three dental instruments: A periodontal probe, a scaler, and an explorer, which can be used for training students in various aspects of periodontology.

Diagnosis: Diagnosing the periodontal disease mainly depends on probing and measuring the clinical attachment loss. Probing depth measurement vary from examiner to examiner because of variation in angulation, pressure, force etc., and thus virtual periodontal probe could be

used to teach the correct probing technique, which will help in determining the health and severity of disease of periodontal tissue and thus the correct diagnosis.

Treatment: Main etiological factors of periodontal disease are plaque and calculus, and thus the treatment of periodontal disease revolves around complete elimination of these etiological factors.

Supragingival calculus which is easily seen can be removed effectively using scalers, but the problem arises in completely removing the sub-gingival calculus, which mainly depends on tactile sensation, which can be achieved using a haptic technology while learning.

A virtual periodontal scaler with two models of gingiva, transparent and opaque, could be used for this purpose. With the opaque model where the tooth surface is covered by gingiva, the haptic device will provide the tactile sensation to evaluate virtual calculus present on the root surface, and with the transparent gingiva, calculus can be concomitantly seen under the gum line. Further virtual explorer can be used to evaluate that the calculus has been completely removed, which could be performed with both a transparent and an opaque gingiva.

### Advantages

1. Reinforcement of learned dental concepts
2. Correct use of dental instruments
3. Correct ergonomic positioning: Incorrect operator or patient positioning can result in blocking the camera from reading the LED sensors and prevents the user from continuing by warning signals. This encourages the students to practice good ergonomic habits
4. Good psychomotor skills[4]
5. Self-evaluation: Students have immediate, unlimited, and objective access to detailed feedback of their work
6. Standardized evaluation
7. Faster acquisition of skills: Students attain a competency-based skill level at a faster rate than with traditional simulator units (phantom heads). This can result in changes in dental curriculum and earlier entrance into the pre-doctoral clinic
8. Positive student perception.[5]

### Disadvantages

1. Virtual of augmented reality dental simulators are at an early or experimental stage
2. A system limitation with the current design: The tactile perception for gingiva is not very real
3. The initial cost of this advanced technology simulation can be substantial. Difficult equipment to maintain and repair: Technology-based systems require faculty/engineering staff to be available for training and supervision of the laboratory. Virtual reality is the next step in dental education. The technologies of virtual reality innovate how clinical training takes place. Unlike existing systems for clinical courses, virtual reality systems overcome the limitations of phantom head systems and provide standardized case, objective assessment, and interactivity. They encourage a self-assessment process to identify self-directed learning and should become an integral part of any student training program.

### References

1. Buchanan JA. Use of simulation technology in dental education. *J Dent Educ.* 2001;65:1225–31. [PubMed]
2. Steinberg AD, Banerjee P, Drummond J, Zefran M. Progress in the development of a haptic/virtual reality simulation program for scaling and root planning. *J Dent Educ.* 2003;67:161–5.
3. Luciano C, Banerjee P, DeFanti T. Haptics-based virtual reality periodontal training simulator. *Virtual Real.* 2009;2:69–85.
4. Lefroy J, Brosnan C, Creavin S. Some like it hot: Medical student views on choosing the emotional level of a simulation. *Med Educ.* 2011;45:354–61. [PubMed]
5. Bal GB, Weiss EL, Gafne N, Ziv A. Preliminary assessment of faculty and student perception of a haptic virtual reality simulator for training dental manual dexterity. *J Dent Educ.* 2011;75:496–504. [PubMed]

# Photodynamic Therapy

Dr. Poonam Kedar<sup>1</sup>, Dr. Shraddha Bhandari<sup>2</sup>, Dr. Maya Mhaske<sup>3</sup>, Dr. Vrunda Kanjalkar<sup>4</sup>

<sup>1</sup>PG Student, Dept. Of Periodontology.

<sup>2</sup>PG Student, Dept. Of Periodontology.

<sup>3</sup>Professor & HOD, Dept. Of Periodontology.

<sup>4</sup>Professor Dept. Of Oral Pathology

## Abstract

Photodynamic therapy (PDT) is a form of phototherapy using nontoxic light-sensitive compounds that are exposed selectively to light, whereupon they become toxic to targeted malignant and other diseased cells. It involves the use of low power lasers with appropriate wavelength to kill microorganisms treated with a photosensitizer drug. PDT could be a useful adjunct to mechanical as well as antibiotics in eliminating periopathogenic bacteria. Applications of photodynamic therapy in dentistry are growing rapidly for the treatment of oral cancer, bacterial and fungal infections and photodynamic diagnosis of malignant transformation of oral lesions, and are recognized as a treatment strategy which is both minimally invasive and minimally toxic.

**Keywords** Photodynamic therapy, photosensitizers, periodontitis.

## Introduction

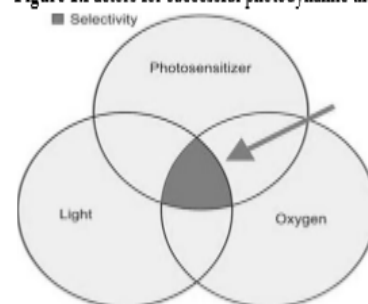
The main objective of periodontal therapy is to eliminate deposits of bacteria and bacterial niches by removing the supragingival and subgingival biofilm.<sup>1</sup> In the treatment of periodontally involved teeth, current concepts are based on mechanical scaling and root planing to remove bacterial deposits, calculus, and cementum contaminated by bacteria and endotoxins. Some therapeutic alternatives, such as systemic and local antibiotics, have been used in cases not responding to conventional treatments, although this therapy brings undesirable side effects like the emergence of resistant microorganisms and a shift in the microflora after extended use which limit the use of antimicrobials.<sup>2</sup>

Recent advances in technology have led to a constant drive to develop novel approaches for the treatment of periodontal diseases. The need to find more optimal treatment protocols for periodontal disease is a long-term goal for periodontal researchers and clinicians. A novel noninvasive photochemical approach for infection control, namely photodynamic therapy, has been receiving much attention in the treatment of oral diseases.<sup>1</sup> Photodynamic therapy (PDT), also known as photoradiation therapy, phototherapy, or photochemo-therapy.<sup>3</sup>

Photodynamic therapy (PDT) was introduced in medical therapy in 1904 as the light-induced inactivation of cells, microorganisms or molecules and is based on the principle that a photosensitizer (i.e. a photoactivatable substance) binds to the target cells and can be activated by light of a suitable wavelength in the presence of oxygen (Fig. 1).<sup>3,4</sup> The exposure of the

photosensitizer to light results in the formation of toxic oxygen species, causing localized photodamage and cell death. Clinically, this reaction is cytotoxic and vasculotoxic.<sup>5</sup> The oral cavity is especially suitable for photodynamic therapy (PDT) because it is relatively accessible to illumination.<sup>3,5</sup> This review is aimed to discuss the role of PDT in periodontal therapy.

Figure 1. Factors for successful photodynamic therapy



## MECHANISM OF ACTION

The basis of PDT is the interaction of light with photosensitive agents to produce an energy transfer and a local chemical effect. Here, many photosensitizers work together to harvest light energy to produce chemical reactions. Of the many photosensitizers that have been used in PDT, each has its own unique excitation properties. Usually, the photosensitizer is excited from a ground singlet state to an excited singlet state. It then undergoes intersystem crossing to a longer-lived excited triplet state. One of the few chemical species present in tissue with a ground triplet

state is molecular oxygen. When the photosensitizer and an oxygen molecule are in proximity, an energy transfer can take place that allows the photosensitizer to relax to its ground singlet state, and create an excited singlet state oxygen molecule. Singlet oxygen is a very aggressive chemical species and will very rapidly react with any nearby biomolecules. Ultimately, these destructive reactions will kill cells through apoptosis or necrosis. PDT can be considered a form of targeted singlet oxygen chemotherapy, where the targeting is achieved with the combination of the photosensitizer (functioning as a catalyst) and intense light.

**ADVANTAGES OF PDT**

Therapy has only localized effects as the photosensitizer is selectively absorbed at a greater rate by target tissues, can be performed in outpatient or day-case settings, is more economical than radiation and surgical therapy for cancer patients, shows faster post-operative healing with no long term side effects, less invasive and can be repeated many times at the same site if needed, unlike radiation<sup>[6]</sup>.

PDT presents some advantages over conventional antibiotic therapy, such as rapid elimination of target microorganisms (within seconds or minutes, depending on energy density and power used) and absence of maintenance of high concentrations of dye on lesions during hours or days as observed in conventional therapy. Due to production of singlet oxygen and free radicals, which are responsible for mediating bacterial killing, the development of resistance to lethal photosensitization by the target organisms would be a very unlikely event. Another advantage relates to the restriction of antimicrobial effects to the lesion through careful application of the dye and light source, without affecting the adjacent normal microflora. Also, PDT acts eliminating diseasecausative microorganisms and their virulence factors<sup>[7]</sup>.

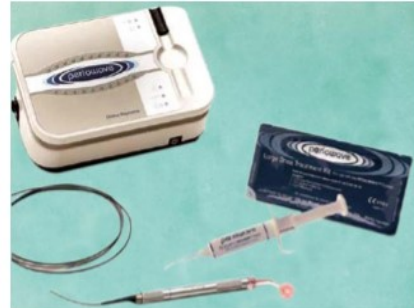**LIMITATIONS**

Light needed to activate photosensitizer cannot penetrate more than 1cm of tissue depth using standard laser and low powered LED technology and hence is less effective in treatment of large tumors and metastasis. It may leave many people very sensitive to light post therapy and cannot be used in people allergic to porphyrins.<sup>[6]</sup>

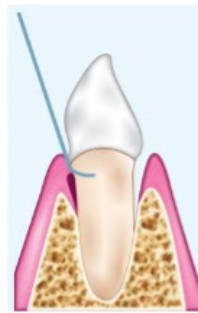
**APPLICATION OF PHOTODYNAMIC THERAPY IN DENTISTRY**

Photodynamic therapy has been used in (i) photodynamic diagnosis of malignant transformation of oral lesions, (ii) treatment of premalignant and

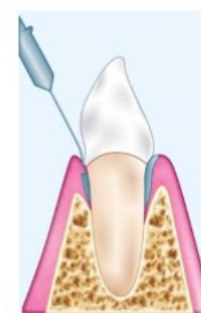malignant oral lesions, (iii) chemotherapy (PACT) of bacterial and fungal infections, (iv) prevention of alveolar osteitis and post extraction pain, (v) decontamination of implant surface and prevention and treatment of peri-implantitis, (vi) endodontic treatment<sup>[8]</sup>.



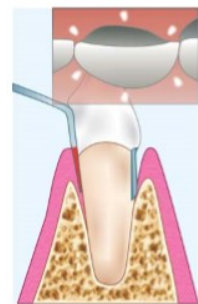PDT Perio Kit



Scaling



Photosensitizer Application



Photosensitizer Activation

**PHOTODYNAMIC ANTIMICROBIAL CHEMOTHERAPY**

Antimicrobial PDT can be considered as an adjunctive to conventional mechanical therapy. The liquid photosensitizer placed directly in the periodontal pocket can easily access the whole root surface before activation by the laser light through an optical fiber placed directly in the pocket<sup>[9]</sup>. As a result of the technical simplicity and the effective bacterial killing, the application of PDT in the treatment of periodontal diseases has been studied extensively.

Antimicrobial PDT not only kills the bacteria, but may also lead to the detoxification of endotoxins such as



lipopolysaccharide. These lipopolysaccharides treated by PDT do not stimulate the production of pro-inflammatory cytokines by mononuclear cells. Thus, PDT inactivate endotoxins by decreasing their biological activity<sup>[10]</sup>.

It has been demonstrated that bacteria associated with periodontal disease can be killed through photosensitization with toluidine blue O by irradiating with helium – neon soft laser. Data from an in vitro study indicated that PDT could kill bacteria organized in a biofilm. In an animal study, it was found that PDT was useful in reducing the redness, bleeding on probing, and Porphyromonas gingivalis levels<sup>[11]</sup>.

### **AN ADJUNCT IN NON-SURGICAL PERIODONTAL TREATMENT**

Twenty-four subjects with chronic periodontitis were randomly treated with scaling and root planning followed by a single episode of PDT (test) and scaling and root planing alone (control). Gingival recession, and clinical attachment level (CAL) were measured at baseline and three, six months after therapy and it was concluded that the additional application of a single episode of PDT to scaling and root planing failed to result in an additional improvement in terms of pocket depth reduction and CAL gain, but it resulted in a significantly higher reduction in bleeding scores compared to scaling and root planning alone. Although mechanical removal of the periodontal pathogens is the current gold standard of treatment in periodontics, antibiotics are also known to be effective.

The use of antibiotics to destroy microorganisms (MO) selectively represents one of the most revolutionary progresses made in scientific medicine, resulting in the treatment and sometimes complete eradication of earlier incurable diseases. However, bacteria have developed resistance mechanisms against antimicrobial drugs which were previously highly effective. Besides, bacteria replicate very rapidly and a mutation that helps a MO to survive in the presence of an antibiotic will quickly become predominant in the microbial population.

The use of photoactivable compounds or photosensitizers (PS) to cause photodestruction of oral bacteria has been demonstrated, indicating that photodynamic therapy (PDT) could be a useful alternative to mechanical means as well as antibiotics in eliminating periopathogenic bacteria. Antimicrobial photodynamic therapy (aPDT) represents a potential alternative methodology to inactivate microbial cells and has already shown to be effective in vitro against bacteria, fungi, viruses, and protozoa<sup>[12]</sup>

### **EFFECT OF PDT ON PERIODONTAL BONE LOSS IN DENTAL FURCATION**

The use of PDT in furcation involvement in induced periodontitis shows some advantages over the use of conventional antimicrobials, such as the reduced need for flap procedures and shorter treatment time; as local therapy, with lack of micro flora disturbance in other sites of the oral cavity. PDT is also beneficial during the maintenance of periodontal therapy because it may act on the biofilm and eliminate the need for the removal of additional root substance by mechanical retreatment. Thus, the patient may experience less dentinal hypersensitivity. This therapy also serves as an adjunct to mechanical therapy in sites with difficult access.<sup>[13]</sup>

### **EFFECT OF A PDT ON PERI-IMPLANTITIS**

Peri-implantitis seems to occur in 5-10% of all implant cases. In this way, photodynamic therapy can be used successfully to decontaminate the implant surface. Laser PDT can be used in implantology to promote osseointegration and to prevent peri-implantitis. Studies have shown that laser photobiomodulation can be successfully used to improve bone quality around dental implants, allowing early wearing of prostheses. The results of a study showed significant differences on the concentration of calcium hydroxyapatite on irradiated and control specimens and concluded that infrared laser photobiomodulation does improve bone healing. The percentage of bone fill and re-osseointegration also improved with photobiomodulation<sup>[14]</sup>.

One of the most interesting developments over the last years has been the introduction of the 9.6- $\mu\text{m}$  CO<sub>2</sub> laser. It has been shown in the recent literature that the use of this new device can preserve tissue, with almost no adverse effects at the light microscopic level. Intraoperatively used PDT or periimplant care of failing implants with the CO<sub>2</sub> laser seems to be more of value than the conventional methods. Data suggest that lethal photosensitization may have potential in the treatment of periimplantitis<sup>[14]</sup>.

Antimicrobial PDT seems to be a unique and interesting therapeutic approach towards periodontal therapy. PDT application has an adjunctive benefit besides mechanical treatment at sites with difficult access (e.g. furcations, deep invaginations, concavities). Necessity for flap operations may be reduced, patient comfort may increase and treatment time decrease. PDT removes the biofilm in residual deep pockets during maintenance; no more root substance is removed by mechanical retreatment. Thus the patient may experience less dentinal hypersensitivity. PDT may decrease the risk of

bacteremia, which routinely occurs after periodontal treatment procedure. Antimicrobial photodynamic therapy may hold promise as a substitute for currently available chemotherapy in the treatment of periodontal and peri-implant diseases. Its nonsurgical profile improves the comfort of treatment and thus makes the process more attractive to patients. Its ease of use makes it suitable for dentists. Treatment regimens still have to be optimized and standardized for better therapeutic effectiveness. Severe side effects have been reported when using inappropriate PDT schedules. Appropriate choices of drug type and dose, light wavelength, and drug–light interval can improve the efficacy and safety of PDT. Furthermore, careful attention to the physics and dosimetry of light will help to minimize toxicity.

## References

- [1]. A. Takasaki, A. Aoki, K. Mizutani, F. Schwarz And A. Sculean, *Periodontology* 2000,51, 2009, 109–140.
- [2]. S.Rajesh,ElizabethKoshi,KoshiPhilip,AparnaMohan, Antimicrobial photodynamic therapy: An overview, *Journal of Indian Society of Periodontology* 15(4), 2011, 323-327.
- [3]. K. Konopka1 and T. Goslinski, Photodynamic Therapy in Dentistry, *Critical Reviews In Oral Biology & Medicine, Journal of Dental Research*, 86(8), 2007, 694-707.
- [4]. Von Tappeiner H, JodlbauerAÜberdieWirkung der photodynamischen (fluoreszierenden) Stoffe auf Protozoen und Enzyme. *Dtsch Arch Klin Med* 39, 1904, 427–487.
- [5]. Shivakumar V., Shanmugam M., Sudhir G, PavithraPriyadarshoni S Scope of photodynamic therapy in periodontics and other fields of dentistry, *Journal of Interdisciplinary Dentistry*, 2(2),2012, 78-83.
- [6]. Veerendra Nath Reddy, Rekha Rani K, Chandana G et al. Photodynamic Therapy. *IJDA Volume 01 Issue 01*.
- [7].Fabiano Dalla Lana Mattiello, Alan Augusto Kalife Coelho, Odair Pimentel Martins et al. In *Streptococcus sanguinis*. *Braz. Dent. J.*2011. vol.22 no.5.
- [8] Sruthima NVS Gottumukkala, Satyanarayana Raju Mantena. Photodynamics in antimicrobial periodontal therapy. *Indian J Oral Sci* 2012;3 (1):8-12
- [9] Andersen R, Loebel N, Hammond D, Wilson M. Treatment of periodontal diseases by photodisinfection compared to scaling and root planing. *J Clin Dent.* 2007; 18:34–8.
- [10]. Rajesh, Elizabeth Koshi, Koshi Philip, and Aparna Mohan. Antimicrobial photodynamic therapy: An overview. *J Indian Soc Periodontal.* 2011 Oct-Dec; 15(4): 323–327.
- [11]. Sigusch BW, Pfitzner A, Albrecht V, Glockmann E. Efficacy of photodynamic therapy on inflammatory signs and two selected periodontopathogenic species in a beagle dog model. *J Periodontol.* 2005; 76:1100–5.
- [12]. Sruthima NVS Gottumukkala, Satyanarayana Raju Mantena. Photodynamics in antimicrobial periodontal therapy. *Indian J Oral Sci* 2012;3 (1):8-12
- [13] Rajvir Malik, Anish Manocha, DK Suresh. Photodynamic therapy - A strategic review: *Indian Journal of Dental Research.* 2010, vol.21, issue 2, page no: 285-291.
- [14] Shibli JA, Martins MC, Nociti FH Jr, Garcia VG, Marcantonio E Jr. Treatment of ligature-induced peri-implantitis by lethal photosensitization and guided bone regeneration: a preliminary histologic study in dogs. *J Periodontal* 2003; 74:338-45.
- [15] Dortbudak O, Haas R, Bernhart T. Lethal photosensitization for decontamination of implant surfaces in the treatment of peri-implantitis. *Clin Oral Implants Res* 2001; 12:104-8

---

# Ligaplant

Dr. Shraddha Bhandari<sup>1</sup>, Dr. Poonam Kedar<sup>2</sup>, Dr. Maya Mhaske<sup>3</sup>

<sup>1</sup>PG Student ,Dept. Of Periodontology.

<sup>2</sup>PG Student ,Dept. Of Periodontology.

<sup>3</sup>Professor & HOD, Dept. Of Periodontology.

---

## Abstract

Periodontitis is the disease causing the destruction of the soft and hard tissues surrounding the tooth. If left untreated, periodontal destruction may progress and lead to mobility and ultimately loss of teeth. Replacement of the missing tooth with implant has gained popularity among the population. The advent of periodontal tissue engineering has revolutionized not only periodontology but also implant dentistry at large. This review article highlights the tissue engineered periodontal ligament on implants, which is going to change the traditional way of implant treatment.

**Keywords** Periodontal ligament, tissue engineering, tooth implant.

## Introduction

Nowadays, fixed and removable partial dentures are replaced by implants, which holds ideal for replacing missing tooth. For implant to be successful factor such as sufficient bone [height and width] is very crucial. Before replacement of the implant, local bone defects and generally poor bone quality necessitate bone reconstruction<sup>1</sup>.

Besides that, localized bone loss around the implant fixture represents the clinical challenge, especially in the case of gingival recession, which requires further surgical interventions. However, problems still exist with these implants as they lack PDL, because any inflammation around them may cause serious bone loss than does the inflammation around the natural tooth with PDL. In addition, these implants are ankylosed and do not have the same mobility as the natural teeth. Currently, Osseointegrated implants are generally agreed to be the most acceptable implants because of their long term clinical survival rate. These problems could be resolved, if implant with PDL could be developed this is achieved by LIGAPLANTS, which is nothing but combination of the PDL cells with implant biomaterial.<sup>2</sup>

## Method of obtaining ligaplant

Tooth transplantation with double PDL stimulation is one of the best examples of its healing capacity. Using this model in its biological and clinical aspect, we now use it similar cell culture around an artificial root using tissue engineering techniques.

## Preparation of temperature-responsive culture dishes

N-isopropylacrylamide monomer in 2-propanol solution was spread onto polystyrene culture dishes. Then the dishes were subjected to electron beam irradiation with an Area Beam Electron Processing System. The temperature-responsive polymer-grafted (poly Nisopropylacrylamide) dishes were rinsed with cold water to remove ungrafted monomer and sterilized with ethylene oxide

## Cells and Cell Culture

Human periodontal ligament cells were isolated from an extracted tooth. After extraction, periodontal tissue was scraped from the middle third of the root with a scalpel blade. The harvested tissue was placed into culture dishes containing = Dulbecco's modified Eagle's minimal essential medium, supplemented with 10% fetal bovine serum and 100 units/mL of penicillin, streptomycin. Then, those outgrowth cells were cultured in a humidified atmosphere of 5% CO<sub>2</sub> at 37°C for 48 hours to allow attachment of the cells to the dishes. The dishes were washed to eliminate debris and the medium was changed three times per week. To harvest the cellsheet, human periodontal ligament cells were plated on temperature-responsive culture dishes (35 mm diameter) at a cell density of 1x10<sup>5</sup> and cultured at 37°C supplemented with 50 mg/mL ascorbic acid 2-phosphate, 10 nM dexamethasone and 10nM β-glycerophosphate that function as an osteodifferentiation medium.

### Culture of PDL cells in a bioreactor

A titanium pin which coated with hydroxyapatite (HAP) was placed in a hollow plastic cylinder leaving a gap of 3mm around the pin. Culture medium was continuously pumped through the gap. Single cells suspension, obtained from human, were seeded first into plastic vessels under a flow of growth medium for 18 days<sup>3</sup>  
 Study Models used were: Nude Athymic mice (Fig 2), Canine model in beagle dogs (Fig 3), (Fig 4), Human clinical Trials (Fig 5)

### Advantages of using Ligaplant

1. Ligaplots can alleviate problems that implant commonly faced such as gingival recession and bone defects of the missing tooth site. Therefore implant can be applied in cases of periodontal bony defects, situation that conventional implants could not be installed.
2. Ligaplant system mimics the natural insertion of natural tooth roots in alveolar bone.
3. Ligaplots become firmly integrated without interlocking and without direct bone contacts, despite the initial fitting being loose in order to spare the PDL cell cushion. Bone formation was induced and movements of ligaplots inside the bone suggesting an intact tissue communication between bone and the implant surface.
4. Provides Proprioception<sup>4</sup>

### Disadvantages

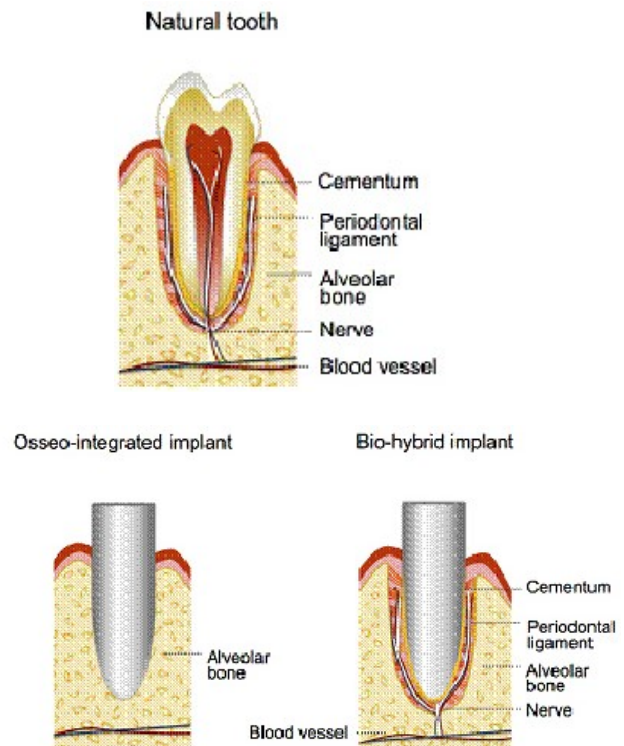
1. The culturing of ligaplots should be cautious about the temperature, the obtained cells that used for culturing, the duration of the culturing and others.
2. If some problem evokes during the culturing, the ligaplots may fail as other nonperiodontal cells may develop. Besides that, with limited facilities and members to perform this research, the cost of this type of implant is high.
3. The factors affecting the host to accept the implant or the growth of PDL in the socket is unpredictable, which may result in failure of implant<sup>3</sup>.

### Properties of Ligaplant

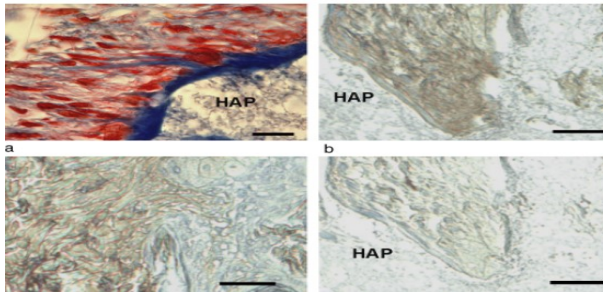
1. PDL cells act as a soft, richly vascular, and cellular connective tissue which permits forces elicited during masticatory function and other contact movements to be distributed to the alveolar process via alveolar bone proper.
2. It act as a, shock absorber giving the tooth some movement in the socket.
3. It provides Proprioception.

4. Periodontal ligament homes vital cells like osteoclast, osteoblast, fibroblast, cementoclast, cementoblast and most importantly undifferentiated stem cells which are osteoconductive in nature.<sup>5</sup>
5. Natural implant anchoring might also be compatible with further growth and development of the alveolar bone housing, and it may allow tooth movements during orthodontic therapy.<sup>6</sup>

Most of these studies are carried out in animals and has been revealed that generating a periodontal-like tissue around implants is possible, still a predictable and feasible method for producing dental implants with periodontal-like ligament has not been innovated and more studies are required in clinicals especially in humans in order to know its long term stability, function, survival and success of these implants. Ligaplots as teeth replacement seems to have decisive advantages as compared with osseointegrated implant, due to their periodontal tissue regeneration and can be the next advancement in the field of implant dentistry.

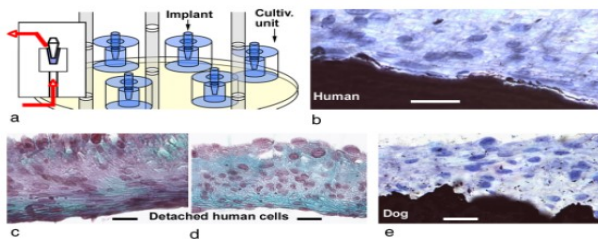


**Fig. 1 Difference in Natural tooth, Osseointegrated implant, Ligaplant**

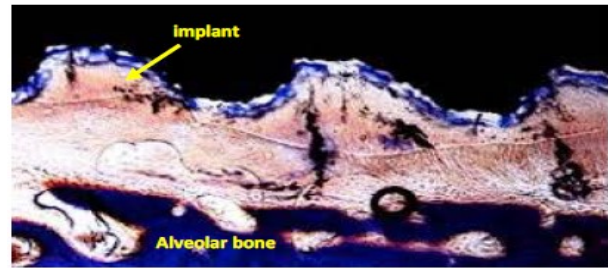


**Fig. 2.** Formation of periodontal ligament (PDL)-like structures by implantation of human

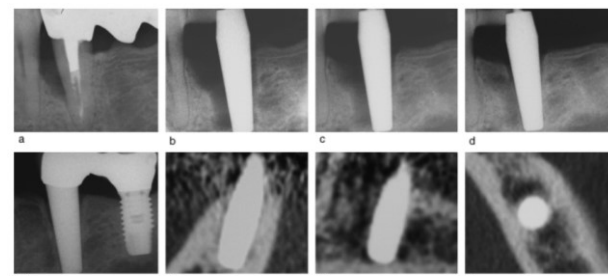
PDL cells into nude athymic mice. Cells were harvested, grown in vitro, seeded on granular hydroxyapatite (HAP) and implanted subcutaneously into the neck region of mice. After 12 weeks, mice were sacrificed, and the implanted material was analysed histologically. (a) Cells and extracellular fibres arranged into PDL-like structures. (b) Immunostaining using antihuman collagen type I serum (brown) indicated the human origin of the HAP-associated fibres. (c) Staining with anti-mouse collagen type I serum revealed mouse collagen in scar tissue. (d) HAP-associated fibres are not stained with anti-mouse serum. Scale bar: 20 mm (a), 40 mm (b–d).



**Fig. 3.** Assembly of human and canine periodontal ligament (PDL) cells with Ti implants, resulting in ligaplants. (a) Bioreactor; cell suspensions were seeded on apatite-covered coneshaped Ti cylinders (implant, vertical) and incubated in plastic vessels (cultivation unit) under a flow of growth medium (inset, red arrows) for 18 days. (c and d) Cell cushions were detached from the ligaplant to prepare paraffin sections (Richardson’s stain). (b and e) Ligaplants were embedded in plastic and ground sections were prepared (methylene blue stain). Scale bars: 10 mm.



**Fig 4:** Masson’s trichrome staining; a new layer of dense collagen covered the ligaplant (d, arrows), and a PDL-like tissue had been formed with perpendicular fibres between implant and alveolar bone.



**Fig. 5.** Ligaplant radiography. (a) Before surgery, root fracture in tooth #34 plus bone defect mesially (left) to the fractured root. (b) Same location immediately after ligaplant implantation. (c) Partial bone regeneration after 24 weeks. (d) After 24 months, note the almost complete replenishment of the major defect. (e) Forty-two months; the periodontium has partially restructured with a fairly regular desmodontal space and reinforced bony demarcation around this space. (f–h) Tomography analysis after 24 months; frontal view (f), side view (g), top view (h). The ligaplant is surrounded by bone trabeculae. Ligaplant dimensions: 15mm in length, 5–7mm in width.

## References

1. Sennerby L, Rocci A, Becker W, Jonsson L, Johansson LÅ, Albrektsson T. Short-term clinical results of Nobel Direct implants: a retrospective multicentre analysis. *Clin Oral Implants Res* 2008;19(3):219-26.
2. Bharathi D, 1 Siji Jacob T, 2 Srinivasan, 3 Senthil Kumar S LIGAPLANTS – A REVIEW *Annals of Dental Specialty* Vol. 5; Issue 2. Apr – Jun 2017
3. Annie Ling SieKiong ,Dr.RhadikaArjunkumar Tissue-engineered Ligament: Implant constructs for Tooth Replacement (Ligaplants) *J. Pharm. Sci. & Res.* Vol. 6(3), 2014, 158-160
4. Gault P, Black A, Romette J-L, Fuente F, Schroeder K, Brune T, Berdal A, Wurtz T. Tissue-engineered ligament: implant constructs for tooth replacement. *J Clin Periodontol* 2010;37, 750-758
5. Benjamin A, Mahajan R, Sura S, Suthar N. 'Ligaplants' The Next Generation Implants. *IJIRS* 2014;3(7): 571-9.
6. Kiong AL, Arjunkumar R. Tissue-engineered Ligament: Implant constructs for Tooth Replacement (Ligaplants). *J Pharm Sci Res* 2014;6(3):158-160

# New Classification Of The Endo-Perio Continuum: A Review

Dr. Arshia R Baig<sup>1</sup>, Dr. Sadashiv Daokar<sup>2</sup>

<sup>1</sup>Lectural, Dept Of Conservative Dentistry & Endodontics

<sup>2</sup>Professor & HOD Dept Of Conservative Dentistry & Endodontics

## Abstract

The coordinated presence of pulpal problems and inflammatory periodontal disease can confuse the diagnosis and treatment planning. An endo-perio lesion can have a diverse pathogenesis which varies from simple to comparatively complex one. The differential diagnosis of endodontic and periodontal diseases can sometimes be difficult, but it is of vital importance to make a correct diagnosis for providing the appropriate treatment. This paper highlights a modified clinical classification that can be taken into consideration for precisely diagnosing and treating an endo-perio lesion.

## Introduction

There is a close relationship between the periodontium and the endodontium. The analysis and prognosis of endo-perio lesions are challenging for a clinician. Such lesions are characterized by the association of pulp and periodontal disease in the same tooth. Simring and Goldberg (1964) first described the relationship between pulpal and periodontal disease.<sup>1,2</sup> The term perio-endo lesion is used to describe those lesions that exist due to the inflammatory products, found in varying degrees in both pulpal and periodontal diseases. Several studies recommend that the consequence of periodontal disease on the pulp is deteriorating in nature, comprising of rise in calcifications, fibrosis and resorption of collagen, in addition to the direct inflammatory sequelae, thus resulting in pulpal necrosis.<sup>2,3</sup>

## PATHWAYS<sup>4</sup>

The main pathways that are responsible for the perio-endo lesions are:

- 1) Tubular Pathways
  - i) Dentinal Tubules.
- 2) Anatomical Pathways
  - i) Lateral and Accessory root canals.
  - ii) Apical Foramen<sup>5</sup>
- 3) Non-physiological pathways
  - i) Iatrogenic Root canal Perforations.
  - ii) Vertical root fractures.<sup>6</sup>

## ETIOPATHOGENESIS OF PERIO-ENDO LESIONS<sup>4</sup> (Fig 1)

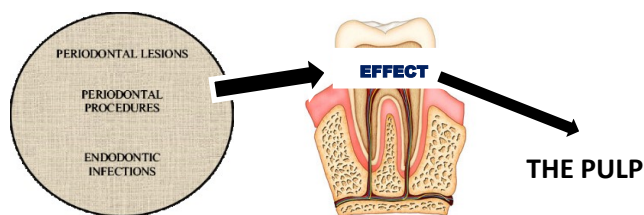


Fig 1: Etiopathogenesis of Perio-Endo Lesion

## CLASSIFICATION OF PERIODONTAL-ENDODONTIC LESIONS

There is a close relationship between the periodontal disease and the pulp. Most commonly referred Classification was given by Simon, Glick and Frank in the year 1972. The classification is as following: (Fig 2)<sup>7</sup>

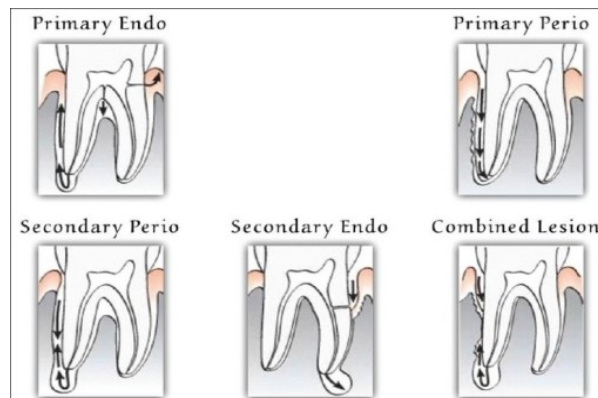


Fig 2: Classification given by Simon, Glick and Frank ( 1972 )<sup>7</sup>

**Clinical Classification given by Torabinejad and Trope in the year 1996**

**(based on the origin of Periodontal pocket):** <sup>8</sup>

- I. Endodontic Origin.
- II. Periodontal Origin.
- III. Combined Endo-Perio Lesion.
- IV. Separate Endodontic and Periodontal lesions.
- V. Lesions with communication.
- VI. Lesions with no communication.

**A NEW CLASSIFICATION OF THE PERIODONTAL ENDODONTIC INTERRELATIONSHIP ( based on the primary disease with its secondary effect), proposed by Al Fouzan (2014), is as following:** <sup>9</sup>

**(1)Retrograde periodontal disease.**

- (a) primary endodontic lesion with drainage through the periodontal ligament,**
- (b) primary endodontic lesion with secondary periodontal involvement.**

**(2)Primary Periodontal Lesion.**

**(3)Primary Periodontal Lesion With Secondary Endodontic Involvement.**

**(4)Combined Endodontic-Periodontal Lesion.**

**(5)Iatrogenic Periodontal Lesions.**

- a) Root perforations.**
- b) Coronal Leakage.**
- c) Dental Injuries or Trauma**
- d) Chemicals used in Dentistry**
- e) Vertical Root Fractures.**

**Discussion**

Pulp and the periodontium are related to each other, through the apical foramen, accessory canals, and dentinal tubules of the root, and one can hinder on the veracity of the other. Even though there is presence of these communication routes, the mechanism of direct spread of the periodontal infection to the pulp is still provocative. <sup>10</sup>

Adriaens et al. reported that the bacteria from the periodontal pockets may contaminate the pulp through the dentinal tubules that would be exposed during procedures like root planning and scaling, thus becoming a reservoir of microorganism resulting in the recolonization of the treated root surface. <sup>11</sup>

Langeland et al. confirmed that if there is involvement of the apical foramen then only pulp would be affected by the periodontal disease. <sup>12</sup>

The differential diagnosis of periodontal and endodontic diseases can occasionally pose difficulty. Endodontic-periodontal lesions pose a challenge to the clinician as far as diagnosis and prognosis of the affected teeth are concerned. Etiological factors such as bacteria, fungi, and viruses as well as other causative factors such as trauma, root resorptions, perforations, and dental malformations also play a vital role in the advancement and development of such lesions. <sup>9</sup>

**Conclusion**

On the basis of current classification, it can be concluded that it is of utmost importance that the dentist should have knowledge to distinguish between the origins of the periodontal-endodontic lesions, comprising all the routes of communication between the pulp and the periodontium, that are probable “connections” for the microorganisms, thus allowing the diffusion of the infection from one location to another.

Thorough knowledge helps in achieving the precise diagnosis and suitable treatment, resulting in better chances of gaining success in the treatment of the periodontal-endodontic lesions.

**References**

- 1.Simring M, Goldberg M. The pulpal pocket approach: Retrograde periodontitis. *J Periodontol.* 1964;35:22–48.
2. Czamecki RT, Schilder H. A histological evaluation of the human pulp in teeth with varying degrees of periodontal disease. *J Endod*1979;5(8):242–253.
- 3.Bender IB, Seltzer S. The effect of periodontal disease on the pulp. *Oral Surgery, Oral Medicine, Oral Pathology.* 1972;33(3):458–474.
4. Sunitha VR, Emmadi P, Namasivayam A, Thyegarajan R, Rajaraman V. The periodontal – endodontic continuum: A review. *J Conserv Dent.* 2008;11:54–62.
5. Rotstein I, Simon JH. Diagnosis, prognosis and decision making in the treatment of combined periodontal-endodontic lesions. *Periodontol* 2000. 2004;34:265–303.
6. Zehnder M, Gold SI, Hasselgren G. Pathologic interaction in pulpal and periodontal tissues. *J Clin Periodontol.* 2002;29:663-671
- 7.Simon JHS, Glick DH, Frank AL. The relationship of endodontic periodontic lesions. *J Period* 1977;43:202
- 8.Torabinejad M, Trope M. Endodontic and periodontal interrelationships,” in *Principles and Practice of Endodontics*, R. E. Walton and M. Torabinejad, Eds., 1996.
- 9.Al-Fouzan KS. A New Classification of Endodontic-Periodontal Lesions. *Int J Dent* 2014.
10. Rubach WC, Mitchell DF. Periodontal disease, accessory canals and pulp pathosis. *Journal Periodontol* 1965;36:34–38.
- 11.Adriaens PA, Edwards CA, de Boever JA, Loesche WJ. Ultrastructural observations on bacterial invasion in cementum and radicular dentin of periodontally diseased human teeth. *J Periodontol* 1988;59(8): 493–503
- 12) K. Langeland K, Rodrigues H, Dowden W. Periodontal disease, bacteria, and pulpal histopathology *Oral Sur Oral Med Oral Pathol* 1974;37(2):257–270



---

# Surgical & Non Surgical Treatment Of Oral Leukoplakia

Dr Pallavi Ambhore<sup>1</sup>, Dr Lata Kale<sup>2</sup>, Dr. Rashmi Phadnis<sup>3</sup>

PG Student Dept Of Oral Medicine & Radiology  
H.O.D Dept Of Oral Medicine & Radiology.

---

## Abstract

Oral leukoplakia is a potential premalignant lesion which has higher rate of malignant transformation so the aim of this review article is to focus on various surgical and non surgical treatment modalities for the treatment of Oral Leukoplakia

**Keywords** Oral leukoplakia, surgical, Non surgical treatment

## Introduction

Oral Leukoplakia (OL) is a potentially malignant lesion that carries the risk of malignant transformation. Smoking, alcohol abuse, lasting mechanical injuries, Candida albicans infection and differences of local galvanic potentials are reported as the most important cause factors. OL can accompany systemic disorders like hormonal disturbances, gastric juice secretion, diminished saliva secretion or iron deficiency anemia. It is also stated that EBV, HPV (16 and 18 types), HSV and HIV viruses significantly influence OL development and carcinogenic transformation<sup>1,2</sup>. In order to conduct treatment for OL, the degree of epithelial dysplasia may be assessed. In the presence of moderate or severe epithelial dysplasia, surgical treatment is recommended. However, OL presenting low to moderate malignant risk may be either completely removed or not, and the decision should consider other factors such as location, size and, in the case of smokers, the patient's engagement in smoking cessation

be performed either through conventional surgery, electro cauterization, laser ablation, or cryosurgery.

The purpose of this paper is to present a review of therapies for OL.<sup>3,4</sup>

## Surgical treatment of oral leukoplakia

The standard treatments for OL range from careful consideration to complete resection

Surgical treatment for OL may prevent the development of oral squamous cell carcinoma, provided by assuring that the resection margins are adequately thick and free of epithelial abnormalities

## Laser

The CO<sub>2</sub> laser has been recommended to treat benign oral lesions as well as premalignant lesions such as OL. The CO<sub>2</sub> laser treatment of potential lesions is most

efficacious when used in defocused mode. It may be assumed that the heat generated can also destroy deeper-lying dysplastic cells

Advantages of lasers include an optimal visualization of the surgical area, seal of lymphatic, and nerve endings which minimizes the chances for neoplastic cells seeding and the elimination of precancerous fields (dysplasia) neighboring the leukoplakia with minimal surgical morbidity<sup>5</sup>

## Nonsurgical treatment of oral leukoplakia

Drug intervention was considered as one of the non-surgical treatment options. Bleomycin, Retinoic acid (vitamin A), and carotenoids

## Carotenoids

### Beta-Carotene

Carotenoids belong to a group of highly hydrophobic molecules with little or no solubility in water [56]. Beta-carotene is a precursor to vitamin A. The use of beta-carotene has been recommended for the prevention of potential malignant lesions, such as OL and cancer, possibly oral cancer.

## Retinoic acid (Vitamin A)

Supplementation with retinoids for OL treatment began in the 1960s. Retinoids interact with surface receptors and penetrate the cell. They are subsequently metabolized and transported to the nucleus through several proteins. Several processes are influenced by retinoids, such as production of keratin, the expression of growth factors and kinases, oncogenesis, apoptosis, production of collagen matrix, immune and inflammatory responses, cell differentiation, embryonic morphogenesis and carcinogenesis.

13-cRA retinoid is recommended for the treatment of OL and use of 13-cRA was shown to be more effective in solving OL<sup>6</sup>

### Lycopene

Lycopene is another nonsurgical treatment for OL. It appears to be a very promising antioxidant as a treatment modality in OL and can protect cells against damage and play a protective role against progression of dysplasia by inhibiting tumor cell proliferation and the first report of efficacy of lycopene against human oral cancer cell was published describing the significant therapeutic effect<sup>7</sup>

### Fenretinide

The compound N-(4-hydroxyphenyl) retinamide, also known as fenretinide (4-HPR) was synthesized in the United States in 1960 and is used for treating OL. This compound, similar to the vitamin A, is used for the chemo preventive treatment of various diseases, and has been studied and tested in clinical trials for the treatment of OL<sup>8</sup>

### Photodynamic therapy

Photodynamic therapy (PDT) is a non-invasive method for the treatment of potential malignant lesions and cancers of the head and neck region. The principle of PDT occurs through photochemical reactions associated with photosensitizing drugs which are photosensitizers, oxygen and visible light. After a period photosensitizer that accumulates in target tissue activated by exposure to low energy visible light with a specific wavelength for the drug.

### Cryotherapy

Cryotherapy is a method that locally destroys lesional tissues by freezing in situ. It has several advantages including bloodless treatment, a very low incidence of secondary infections, and a relative lack of scarring and pain. Cryotherapy can be carried out with either a closed or an open system. Closed-system cryotherapy offers a greater degree of temperature control but requires complex, delicate, and expensive equipment. It is performed by direct contact of the cryoprobe onto the lesional surface. Because of the small and flat contact area of the cryoprobe end, closed-system cryotherapy is usually suitable for treatment of uniform, smooth-surfaced oral lesions less than 1 cm in diameter. Open-system cryotherapy involves directly applying the cryogen to the lesion with a cotton swab or a portable spray apparatus. It is more difficult to maintain a constant lower temperature in the lesional tissues during the whole treatment period. However, it does not need

expensive equipment. Open-system cryotherapy with the spray apparatus is suitable for treatment of medium and large oral lesions with either a smooth or a rough surface. Several clinical trials have investigated the treatment of OL patients with the use of supplements. The intervention should be considered in accordance with the result of the biopsy. However, OL presenting low to moderate malignant risk may be either completely removed or not, and the decision should consider other factors such as location and size. Both surgical and nonsurgical methods demonstrated great effectiveness in accordance with the degree of dysplasia. Surgical treatment of OL may be performed through conventional surgery. The causative agent of OL must be abandoned so that the follow-up treatment is successful. Although the administration of retinoic acid and beta-carotene has some efficacy to resolve OL. Given the side effects and counter-indications of antioxidizing agents, with the exception of lycopene, the use of agents requires careful control. At this time, randomized controlled trials for treatments of OL demonstrate no evidence of efficient treatment in preventing malignant transformation and recurrence. It is recommending close lifelong follow-up with new biopsies when changes are detected. It is necessary to strengthen further clinical trials to determine the effectiveness of treatment for the patient according to their follow-up, which allows us to differentiate successfully between surgical cases and observation.

### References

1. Grajewski S, Groneberg D. [Leukoplakia and erythroplakia--two orale precursor lesions]. *Laryngorhinootologie*. 2009; 88: 666-672.
  2. Reichart PA, Philipsen HP. Oral erythroplakia--a review. *Oral Oncol*. 2005; 41: 551-561.
  3. Reibel J. Prognosis of oral pre-malignant lesions: significance of clinical, histopathological, and molecular biological characteristics. *Crit Rev Oral Biol Med*. 2003; 14: 47-62.
  4. van der Waal I, Schepman KP, van der Meij EH, Smeele LE. Oral leukoplakia: a clinicopathological review. *Oral Oncol*. 1997; 33: 291-301.
  5. van der Hem PS, Nauta JM, van der Wal JE, Roodenburg JL. The results of CO2 laser surgery in patients with oral leukoplakia: a 25 year follow up. *Oral Oncol*. 2005; 41: 31-37.
  6. Britton G. Structure and properties of carotenoids in relation to function. *FASEB J*. 1995; 9: 1551-1558.
  7. Uma TN. Treatment of oral leukoplakia with antioxidants-A systematic review. *Int J Pharm Bio Sci*. 2013; 4: 33-34.
  8. Chiesa F, Tradati N, Grigolato R, Boracchi P, Biganzoli E, Crose N, et al. Randomized trial of fenretinide (4-HPR) to prevent recurrences, new localizations and carcinomas in patients operated on for oral leukoplakia: long-term results. *Int J Cancer*. 2005; 115: 625-629.
  9. Arruda JAA, Álvares PR, Sobral APV and Mesquita RA. A Review of the Surgical and Nonsurgical Treatment of Oral Leukoplakia. *J Dent & Oral Disord*. 2016; 2(2): 1009.
- J Dent & Oral Disord - Volume 2 Issue 2 - 2016*

---

# Oral Health: Mirror Of General Health

Dr. Syeda Shadab Farha<sup>1</sup>, Dr. Sonia Sodhi<sup>2</sup>, Dr. Lata Kale<sup>3</sup>, Dr. Vishwas Kadam<sup>4</sup>

<sup>1</sup>PG Student Of Oral Medicine & Radiology

<sup>2</sup>Professor Dept Of Oral Medicine & Radiology

<sup>3</sup>Professor and HOD Of Oral Medicine And Radiology

<sup>4</sup>Reader Department Of Oral Medicine & Radiology

---

## Abstract

The oral cavity is an important anatomical location with a role in many critical physiologic processes. It is unique for the presence of exposed hard tissue surrounded by mucosa. Truly the oral cavity is a mirror that reflects and unravels many of the human body's internal secrets. The oral cavity might well be thought as window to the body because oral manifestations accompany a wide array of systemic diseases. In many instances, oral involvement precedes the appearance of other symptoms or lesions at other locations. The mouth is the major portal of entry to the body and is equipped with formidable mechanisms for sensing the environment and defending against toxins or invading pathogens. The oral cavity can be considered as a window to the body because many important systemic disorders manifest in the oral cavity.

**Keywords** Oral cavity, Systemic disease, diagnosis

## Introduction

The oral cavity is an important anatomical location with a role in many critical physiologic processes, such as digestion, respiration, and speech. It is also unique for the presence of exposed hard tissue surrounded by mucosa. The mouth is frequently involved in conditions that affect the skin or other multiorgan diseases. In many instances, oral involvement precedes the appearance of other symptoms or lesions at other locations. This article is intended as a general overview of conditions that have oral manifestations but also involve other organ systems.<sup>1</sup>Some warning signs of oral infections are:<sup>2</sup>

- Bad breath or bad taste that won't go away
- Red or swollen gums
- Tender or bleeding gums
- Painful chewing
- Loose teeth
- Sensitive teeth
- Gums that have pulled away from your teeth
- Any change in the way your teeth fit together when you bite

## A) GASTROINTESTINAL DISEASES

Oral cavity is the portal of entry to the gastrointestinal tract (GIT). Lined by stratified squamous epithelium, the tissues of the mouth are often involved when individuals have conditions affecting the gastro intestinal system. These may be immune-mediated or chemically mediated processes. Some have postulated that increased dental health and oral

hygiene have led to an immunological imbalance and increased propensity for autoimmunity.<sup>3</sup>

Intraoral involvement in Crohn's disease occurs in 8-29% of patients and may precede intestinal involvement. Orofacial symptoms of Crohn's disease include (1) diffuse labial, gingival, or mucosal swelling; (2) cobblestoning of the buccal mucosa and gingiva; (3) aphthous stomatitis; (4) mucosal tags; and (5) angular cheilitis. Noncaseating granulomas are characteristic of orofacial Crohn disease. Labial swelling is most often a cosmetic complaint, but it can be a painful manifestation of the disease. Gingival and mucosal involvement may cause difficulty while eating. Increased dental caries and nutritional deficiencies may be related to decreased saliva production and mal absorption in the intestinal tract. Oral manifestations can prove crucial in diagnosis and usually parallel the intestinal disease course. Oral involvement may precede systemic manifestations and symptoms. The severity of oral lesions may coincide with the severity of the systemic disease, and it may be used as a marker for intestinal impairment.<sup>4</sup>

## A) RENAL DISEASES

Oral cavity is the mirror of systemic health diseases. Chronic renal failure (CRF) is one such disease which presents with a spectrum of oral manifestations, often due to the disease itself and treatment.<sup>5</sup>

**Uremic Stomatitis**

Uremic stomatitis can be seen due to presence of markedly elevated levels of urea and other nitrogenous wastes in the blood stream of chronic renal failure patients which can be abrupt in onset. It is clinically represents as white plaques distributed predominantly on the buccal mucosa, floor of the mouth and tongue.<sup>6</sup>

**Dry Mouth**

Xerostomia or dry mouth, is a frequent and important complaint among dialysis patients.<sup>12</sup> There are several reasons for the prevalence of dry mouth. The decreased salivary flow may be due to direct uremic involvement of salivary glands, chemical inflammation, dehydration, mouth breathing and also from the restricted fluid intake, irrespective of whether the patient is diabetic or not. The other conditions that may cause dry mouth in uremic patients are retrograde parotitis, metabolic abnormalities and use of diuretics.<sup>5</sup>

**Taste Change**

The cause of metallic taste in uremic patients has been reported to be due to urea content in the saliva and its subsequent breakdown to ammonia and carbon dioxide by bacterial urease. The change in taste can also be due to metabolic disturbance, the use of medication, diminished number of taste buds and changes in the salivary flow and composition. Another study reports that high levels of urea, dimethyl and trimethyl amines and low levels of zinc might be associated with decreased taste perception in uremic patients.<sup>5</sup>

**Mucosal Petechiae and Ecchymosis**

This manifestation may be due to bleeding tendency because of abnormal thrombocyte function and a decrease in platelet factor III. It may also relate to the anticoagulants used during hemodialysis. The association between the prevalence of petechiae and ecchymosis and serum anticoagulant level require further studies.<sup>7</sup>

**B) ENDOCRINE DISORDERS****Diabetes Mellitus (DM)**

About a third of Diabetic patients complain of xerostomia, which may be due to an overall diminished flow of saliva and an increased salivary glucose level. Concomitant diffuse, nontender, bilateral enlargement of the parotid glands, called Diabetic Sialadenosis, may be seen. Altered taste and burning mouth syndrome have been reported in poorly controlled diabetes. Xerostomia may act as a

predisposing factor in the development of the oral infections. Dry and damaged mucosa is more susceptible to opportunistic infections by *Candida albicans*.<sup>8,9</sup>

**Hypoparathyroidism**

It occurs following iatrogenic surgical removal of the parathyroid glands, as well as from autoimmune destruction of the parathyroid tissue. Hypocalcemia follows the loss of parathyroid hormone. Chvostek's sign, an important finding associated with hypocalcemia, is characterized by twitching of the upper lip when the facial nerve is tapped just below the zygomatic process. A positive response suggests a latent degree of tetany. If hypothyroidism develops early in life during tooth development, a pitting enamel hypoplasia and failure of the tooth eruption may occur.<sup>10,11</sup>

**Hypercortisolism Or Cushing's Syndrome**

It results from a sustained increase in blood glucocorticoid levels. Fatty tissue deposition in the facial area is described as the characteristic "moon" facies. Pathological fractures of the mandible, maxilla or alveolar bone may occur upon low impact trauma due to osteoporosis. Healing of fractures as well as healing of alveolar bone and soft tissue after dental extraction is also delayed.<sup>12</sup>

**Hypoadrenocorticism**

It results from insufficient production of adrenal corticosteroid hormones caused by destruction of the adrenal cortex (Addison's disease). Orofacial manifestations include a "bronzing" hyperpigmentation of skin especially sun exposed areas and pressure points. This is caused by increased level of adrenocorticotropic hormone (ACTH). The skin changes are often preceded by oral mucosal melanosis. There is diffuse brown macular pigmentation of buccal mucosa.<sup>12</sup>

**C) HAEMATOLOGIC DISEASES****Anaemia**

It is an abnormal reduction in the number of circulating red blood cells, the quantity of haemoglobin and the volume of packed red cells in a given unit of blood.

In India, Iron deficiency anaemia is the most common type, especially in females and children. Oral manifestations- Pallor of mucosa, generalized atrophy of the tongue and buccal mucosa, angular cheilitis, soreness or burning of tongue, filiform papillae over the anterior two third of the tongue are first to

undergo atrophy. In severe cases fungiform papillae are also affected leaving tongue completely smooth and glistening. Recurrent aphthous ulcerations and candidal lesions can also occur.<sup>13</sup>

### **Pernicious Anaemia**

Tongue is generally inflamed and described as beefy red in colour. Tongue is smooth and bald due to atrophy of papillae referred as Hunter's glossitis. There is disturbance in taste sensation and dryness of the mouth.

### **Aplastic Anaemia**

Petechiae often are present over the soft palate.

### **Plummer-Vinson Syndrome**

It is characterized by dysphagia, iron deficiency anaemia, dystrophy of nails (Koilonychia) and glossitis, seen exclusively in middle aged women. Patients have angular cheilitis, soreness and fissuring of the tongue. Dysphagia is due to pharyngoesophageal ulcerations.

### **Sickle Cell Anaemia**

Oral mucosa show pallor, delayed eruption of teeth. Patient is more prone to develop osteomyelitis, may present with paresthesia of the mental nerve.

### **Leukemia**

The leukemia are malignant neoplasias of WBC precursors characterized by diffuse replacement of bone marrow with proliferating leukemic cells, abnormal number and forms of immature WBC's in the circulating blood, widespread infiltrates in the liver, spleen, lymph nodes and other body sites.

Leukemic gingival enlargement is a common finding, gingiva appears initially bluish red and cyanotic with rounding and tenderness of gingival margin, then it increases in size, covering the crowns of the teeth. Bleeding of gingiva can be an early sign of the leukemia. Other oral signs are petechiae, ecchymosis, mucosal ulcers and haemorrhage.<sup>13</sup>

## **D) CONNECTIVE TISSUE DISORDER**

### **Sjögren's Syndrome**

It is the second most common autoimmune disease, affecting as many as 3% of women aged 50 years or older. The sex predilection is profound: approximately 90% of patients are female. Primary sjögren syndrome is characterized by sicca syndrome, kerato conjunctivitis sicca and xerostomia. A secondary form is associated with rheumatoid arthritis. Oral changes in Sjögren syndrome include difficulty in swallowing and eating, disturbances in

taste and speech, increased dental caries and a predisposition to infection, all due to a decrease in saliva. The inflammation and resultant epithelial hyperplasia render the ducts blocked and useless. This leads to atrophy of the acini, fibrosis and hyalinization of the gland. These changes are irreversible, although certain medications can help to maximize saliva production from the remaining functional glandular tissue. Taken together, these facts reinforce the philosophy that good oral hygiene and frequent dental visits are essential in minimize the deleterious effects of compromised salivary flow.<sup>14</sup>

### **Wegener Granulomatosis**

It is a necrotizing vasculitis of small-to-medium vessels associated with necrotizing granulomas of the upper and lower airways and necrotizing glomerulonephritis. Early diagnosis of this disease is essential in order to prevent the irreversible glomerular damage that can lead to death. Oral involvement in Wegener granulomatosis is common, and autopsy studies of patients with the disease show this site is affected in nearly all cases. Oral lesions include ulcerations and gingival enlargement. The oral ulcerations, which occur on the buccal mucosa or palate, are the most common but least specific oral lesions. The characteristic gingival appearance of Wegener granulomatosis is a pathognomonic finding termed "strawberry gingivitis," although it is less common than other findings. The gingival take on a characteristic swollen, reddened and granular appearance. Initially, bright red-to-purple friable diffuse papules originate on the labial interdental papillae. Involvement may eventually include the lingual and palatal mucosa. Tooth and alveolar bone loss are common. Oral and skin manifestations may correlate with disease progression, thereby providing prognostic value. The discovery of oral lesions during the physical examination can direct the appropriate confirmatory tests to ensure prompt treatment and to prevent further damage to the lungs and kidneys.<sup>15</sup>

### **Sarcoidosis**

It is an idiopathic systemic disease characterized by bilateral hilar lymphadenopathy and noncaseating granulomas in the lungs. Ocular and cutaneous manifestations are common. Sarcoidosis may involve nearly any organ system; organs involved include the liver, heart, spleen, eyes, kidneys and lymph system. Oral manifestations may include multiple, nodular, painless ulcerations of the gingiva, buccal mucosa, labial mucosa and palate. Indistinct ulcerations or swellings do not aid in diagnosing

sarcoidosis, but biopsy results reveal noncaseating granulomas surrounded by multinucleate giant cells along with lymphocytic infiltrate. Although less common, salivary gland involvement is a possibility, leading to tumor like swellings. Heerfordt syndrome may arise if symptoms include parotid gland swelling, xerostomia, uveitis and facial nerve palsy. Rarely, sarcoidosis may involve the tongue, including swelling, enlargement, and ulcerations.<sup>16</sup>

## E) METABOLIC DISORDERS

### Langerhans Cell Histiocytosis

Langerhans cell histiocytosis has replaced the term histiocytosis X, a condition of unknown etiology and pathogenesis characterized by abnormal proliferation of histiocytes and eosinophils. Oral symptoms include large ulcerations, ecchymoses, gingivitis, periodontitis and subsequent tooth loss. A more localized variant, primarily referred to as Hand-Schüller-Christian disease, and is a childhood disease that consists of the triad of diabetes insipidus, lytic bone lesions and proptosis. Oral manifestations include irregular ulcerations of the hard palate, which may be the primary manifestation of the disease. Gingival inflammation and ulcerated nodules, difficulty in chewing and foul-smelling breath also occur. The most common form of Langerhans cell histiocytosis is the eosinophilic granuloma type, which develops in young adults and demonstrate rapid progressive alveolar bone loss with dental extrusion, producing the characteristic appearance of "floating teeth." Oral swellings or ulcerations resulting from mandibular or maxillary bone involvement are common. Oral ulcerations may develop on the gingiva, palate and floor of the mouth, along with a necrotizing gingivitis. Oral lesions may occur without underlying bone destruction. In these rare cases, ulceration of the palate or gingiva may be the primary oral sign.<sup>17</sup>

## CONCLUSION

Many systemic diseases have oral manifestations. The oral cavity might well be thought of as the window to the body because oral manifestations accompany many systemic diseases. These oral manifestations must be properly recognized if the patient is to receive appropriate diagnosis and referral for treatment. Although few systemic diseases have strictly pathognomonic lesions of the oral mucosa, a careful examination of the oral cavity can often lend important clues to making a diagnosis. The diagnosis of oral manifestations of systemic diseases is vital in dentist's perspective. Thus knowledge on the

systemic diseases is important in day to day clinical practice for the dentist.

## References

1. Aframian DJ, Ofir M, Benoliel R. Comparison of oral mucosal pH values in bulimia nervosa, GERD, BMS patients and healthy population. *Oral Dis*, 16(8), 2010, 807-11.
2. Periodontal diseases, Centers for Disease Control and Prevention, [http://www.cdc.gov/oral-health/topics/periodontal\\_disease.htm](http://www.cdc.gov/oral-health/topics/periodontal_disease.htm), Accessed May 05, 2013.
3. Bajaj S Prasad S, Gupta A, Singh VB. Oral manifestations Oral manifestations in type-2 diabetes and related complications. *Indian J Endocrinol Metab*, 16(5), 2012, 777-779.
4. Asha V, Latha S, Pai A, Srinivas K, Ganapathy KS. Oral Manifestations in Diabetic and Nondiabetic Chronic Renal Failure Patients on Hemodialysis *J Indian Aca Oral Med Radiol* 2012;24:274-279.
5. Asha V, Latha S, Pai A, Srinivas K, Ganapathy KS. Oral Manifestations in Diabetic and Nondiabetic Chronic Renal Failure Patients on Hemodialysis *J Indian Aca Oral Med Radiol* 2012;24:274-279.
6. Neville BW, Damm DD, Allen CM. Oral manifestation of systemic diseases. In: Bouquot JE (Ed). *Oral and Maxillofacial Pathology* (2nd ed). USA: WB Saunders Company 2002:705-36.
7. Chuang SF, Sung JM, Kuo SC, Huang JJ, Lee SY. Oral and manifestations in diabetic and nondiabetic uremic patients receiving hemodialysis. *Oral Surg Oral Med Oral Pathol Oral Radiol Endod* 2005;99:689-95.
8. Rees TD. The diabetic dental patient. *Dent Clin North Am* 1994;38(3):447-63. 15. National institute of dental and craniofacial research at the national institutes of health: improving the nation's oral health [Accessed on April 25,2011]
9. Available from: <http://www.nidcr.nih.gov/OralHealth/Topics/Diabetes/default.htm>
10. Spiegel AM. Hypoparathyroidism. In: Wyngaarden JB, Smith LH Jr, Bennett JC, editors. *Cecil's textbook of medicine*. Philadelphia: WB Saunders; 1992:pp 1419-20.
11. Walls AWG, Soames JV. Dental manifestations of autoimmune hypoparathyroidism. *Oral Surg Oral Med Oral Path* 1993;75:445-52.
12. Davenport J, Kellerman C, Reiss D, Harrison L. Addison's disease. *AmFam Physician* 1991;43:1338-42.
13. Lynch MA, ShipII. Intial oral manifestations of leukemia. *J Am Dent Assoc* 1967;75: 932-940.
14. Caldemeyer KS, Parks ET, Mirowski GW. Langerhans cell histiocytosis. *J Am Acad Dermatol*, 44(3), 2001, 509-11.
15. Chen Y, Fang L, Yang X. Cyclic neutropenia presenting as recurrent oral ulcers and periodontitis. *J Clin Pediatr Dent*, 37(3), 2013, 307-8.
16. Chuang TY, Stitle L, Brashear R, Lewis C. Hepatitis C virus and lichen planus, A case-control study of 340 patients. *J Am Acad Dermatol*, 41(5 Pt 1), 1999, 787-9.
17. Darby WJ. The oral manifestations of iron deficiency. *J Am Med Assoc*. 130(13), 1946, 830-835s

---

# Oral Cancer- A Global Burden!!!

Dr. Jyoti S. Khedgikar<sup>1</sup>, Dr. Revati V.Deshmukh<sup>2</sup>

<sup>1</sup>Professor and HOD Oral Pathology and Microbiology

<sup>2</sup>Senior Lecturer Oral Pathology and Microbiology

---

## Abstract

Oral cancer has become a global health problem. It is one amongst the top 3 cancers and around 4 lakh people die because of it annually. As dentists, we owe to the society and it is our moral responsibility to help in lowering this burden. This article is a short attempt towards the same.

Oral cancer is considered as one of the top 3 cancers (lung cancer, cervical cancer and lung cancer) all over the world. Oral cancer accounts for 30% of all cancers and annually 4 lakh people die because of it. Also it has been observed that the age of initiation has lowered below 17 years. Due to limited health providers this burden of oral cancer is increasing.

Hence it has become a global health problem But as they say, prevention is better than cure, prevention of oral cancer will help in reducing this burden....

As per statistics 57% males and 11% females are affected by oral cancer Bhopal, Ahemadabad, Aurangabad, Pune and Thiruvananthapuram are the areas showing more patients of oral cancer.

Main etiological factors for oral cancer are tobacco and areca nut. Chronic use of tobacco in different forms eg khaini pan masala, gutkha, zarda, bidi, mawa, kharra, cigarettes, cigar snuff etc. is very common in India. All these are dry mixtures made with powdered tobacco, areca nut and lime. Betel nut is considered as human carcinogen. Its use with

tobacco releases hydrocarbons and N-Nitrosamines which are toxic, carcinogenic and harmful products.

‘A deep red smile is common sight in many parts of Asia and Pacific’. Chronic tobacco, areca nut and alcohol users are called Psychoactive Persons...

How can we help to reduce this global burden??

\* Not selling tobacco to minors.

By law, selling tobacco to minors is a punishable offence and as per Supreme Court judgement, one can get 7 years jail.

\* Media campaigning to raise awareness. eg. “smoking kills”

\* Awareness about prevention

\* Counselling to stop habits

\* Early detection and screening

We owe to the society, so as per the theme of WHO 2018, “I CAN, WE CAN HELP IN REDUCING THE GLOBAL BURDEN OF CANCER” we, as dentists let us help in preventing and reducing this global burden...

---

# Oral Premalignant Lesions Induced By Smokeless Tobacco

Dr. Pooja B Muley<sup>1</sup>, Dr. Lata Kale<sup>2</sup>, Dr. Sonia Kaur Sodhi<sup>3</sup>, Dr. Vishwas Kadam<sup>4</sup>

1. PG Student, Department Of Oral Medicine & Radiology
  2. Professor & Head O Department Of Oral Medicine & Radiology
  3. Associate Professor Department Of Oral Medicine & Radiology
  4. Reader Department Of Oral Medicine & Radiology
- 

## Abstract

Tobacco in any form can cause wide spectrum of oral mucosal lesions. Tobacco use causes an array of changes in the oral cavity, from mucosal pigmentation to thickening, ulceration of the epithelium. Oral cancer and other oral mucosal lesions such as tobacco induced keratosis, leukoplakia, and submucous fibrosis are strongly associated with tobacco consumption. The prevalence and severity of lesions demonstrate a dose-response relationship, which is best predicted by the amount, frequency and duration of smokeless tobacco use.

**Keywords-** tobacco induced keratosis, leukoplakia, erythroplakia, submucous fibrosis

## Introduction

Tobacco use is one of the most common habit seen in India.<sup>1</sup> India is the second largest producer and consumer of tobacco next only to China.<sup>2</sup> The prevalence of tobacco use among Indian adults is 35%.<sup>3</sup> Tobacco is used in chewable as well as smokable forms. Smokeless tobacco is used in various forms like betel quid which is a mixture of areca nut, slaked lime, and flavoring agent wrapped in betel leaf and tobacco commercial preparations such as gutka, zarda, khaini, mishri, etc., contain the pieces of areca nut coated with powdered tobacco, sweetening and flavoring ingredients in addition to other spices such as saffron, cardamom, etc. which are very popular and highly addictive.<sup>4,5</sup>

Tobacco in any form can cause wide spectrum of oral mucosal lesions. The type and location of these lesions in turn depends on the type, duration of frequency of use. Tobacco use causes an array of changes in the oral cavity, from mucosal pigmentation to thickening, ulceration of the epithelium. Oral cancer and other oral mucosal lesions such as tobacco induced keratosis, leukoplakia, and submucous fibrosis (SMF) are strongly associated with tobacco consumption. In comparison to Western populations, in which oral cancer represents about 3% of malignancies, it accounts for over 30% of all cancers in India; this difference can be attributed to regional variation in the prevalence and pattern of tobacco habits.

## Carcinogens in commonly used smokeless tobacco forms- pan masala and gutkha:

The main carcinogens in pan masala and gutkha are derived from their ingredients areca nut, lime, catechu and tobacco. Several carcinogens are derived from tobacco but also from areca nut . Carcinogenic nitrosamines that could be derived from major ingredients of pan masala (areca nut) and gutkha. The carcinogenic TSNAs(Tobacco-specific nitrosamines) , N<sup>o</sup> -nitrosornicotine (NNN), 4-(N-methyl-N-nitrosamino)-1-(3-pyridyl)-1-butanone (NNK) and N-nitrosoanabasine (NAB), as well as the volatile nitrosamines N- nitrosodimethylamine and N-nitrosodiethylamine, have been detected in the saliva of chewers of BQ with tobacco. Chemical products of smokeless tobacco is nicotine, nitrosamines, nitrosamine acids ,polycyclic aromatic hydrocarbons(PAHS), aldehydes and metals.Tobacco specific nitrosamines are formed from alkaloids during the processing of tobacco leaves. The average consumption in regular users of snuff is about 10-15 g per day. In general the snuff is kept in the oral cavity for several hours per day.<sup>6</sup>

## Terminology and Definitions-

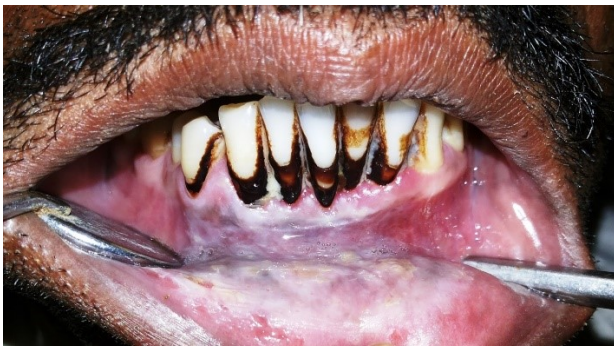Precancerous Lesion can be defined as a benign lesion with morphologically altered clinical or histopathological tissue which has greater than normal risk of containing microscopic focus of cancer or of transforming into malignant lesion after diagnosis at a later date. Precancerous Condition can be defined as a disease or patient habit which does not necessarily alter the clinical appearance of local



tissue but is known to have a greater than normal risk of precancerous lesion or cancer development.<sup>7</sup> Following are the smokeless tobacco induced oral premalignant lesions-

#### **TOBACCO POUCH KERATOSIS:**

Tobacco pouch keratosis is a „ white keratotic oral mucosal changes „ resulting from chronic use of smokeless tobacco. It is only seen where the mucosa is in direct contact with snuff or chewing tobacco and it is also called as snuff dippers keratosis and smokeless tobacco keratosis. Most common area of involvement is the anterior mandibular vestibules followed by the posterior vestibules. The surface of mucosa appears white corrugated or wrinkled area where the tobacco has been placed.<sup>8</sup> The white tobacco pouch may become leathery or nodular in long-term heavy users. The histopathologic appearance of smokeless tobacco keratosis is not specific. Squamous epithelium is hyperkeratinized and acanthotic (Thickened spinous layer with or without intracellular vacuolization or “edema” of glycogen-rich superficial layer.<sup>9</sup>



**Fig. 1-** Tobacco pouch keratosis on lower labial vestibule

#### **LEUKOPLAKIA**

Leukoplakia is defined as “A white plaque of questionable risk having excluded (other) known diseases or disorders that carry no increased risk for cancer”. It should be realized that there are several white lesions, including amalgam associated leukoplakic or lichenoid lesions, that cannot always be clearly distinguished from leukoplakia and yet may carry an increased risk of malignant transformation.<sup>10,11</sup>

Clinically, leukoplakia can be subdivided in a homogeneous type (flat, thin, uniform white in colour) and a non-homogeneous type. The non-homogeneous type has been defined as a white-and-red lesion (“erythroleukoplakia”), that may be either irregularly flat

(speckled) or nodular. Verrucous leukoplakia is yet another type of non-homogeneous leukoplakia. Although verrucous leukoplakia usually has a uniform white appearance, its verrucous texture is the distinguishing feature from homogeneous (flat) leukoplakia.

Proliferative verrucous leukoplakia (PVL) is a subtype of verrucous leukoplakia, being characterized by multifocal presentation, resistance to treatment and a high rate of malignant transformation.<sup>7</sup>

Histopathologically, a distinction can be made between dysplastic and non-dysplastic leukoplakia. There may be considerable intra- and interobserver variation among pathologists in the assessment of the presence and the degree of epithelial dysplasia. Verrucous leukoplakia may show a spectrum of histopathological changes, ranging from hyperkeratosis without dysplasia to verrucous hyperplasia and verrucous carcinoma.

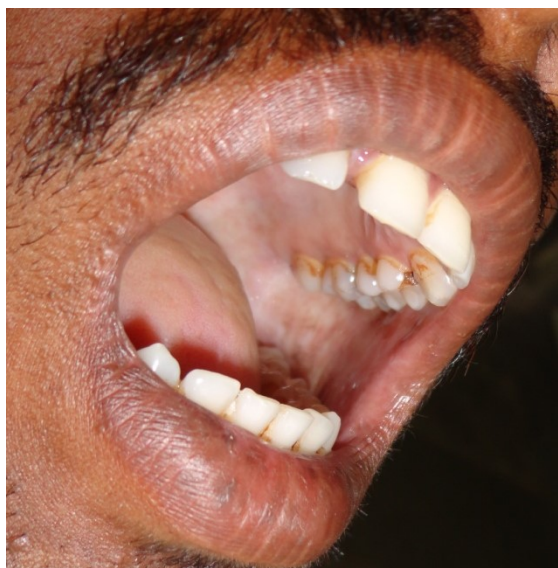An annual malignant transformation rate of approximately 1% is probably a realistic figure for all types of leukoplakia together.<sup>7</sup>

#### **ERYTHROPLAKIA**

Erythroplakia is defined in a similar way as leukoplakia, being a “A fiery red patch that cannot be characterized clinically or pathologically as any other definable disease”.<sup>10</sup> Instead of a patch, the clinical appearance is often a flat or even depressed erythematous change of the mucosa; for that reason the term ‘erythroplasia’ may be more appropriate. In case of a mixture of red and white changes such lesion is categorized as non-homogeneous leukoplakia (‘erythroleukoplakia’). Tobacco and alcohol use are considered important aetiological factors. Reported prevalence figures vary between 0.02% and 0.83%.<sup>12</sup> Erythroplakia mainly occurs in the middle aged and the elderly, usually in a solitary fashion. This solitary presentation is often helpful in clinically distinguishing erythroplakia from erosive lichen planus and erythematous candidiasis, since these lesions occur almost always in a bilateral, more or less symmetrical pattern. Histopathologically, erythroplakia commonly shows at least moderate or severe dysplasia. Probably by far the majority of erythroplakias will undergo malignant transformation.

**ORAL SUBMUCOUS FIBROSIS:** OSF is predominantly caused by the use of areca nut and also occurs in association with smokeless tobacco habit. Besides being regarded as a precancerous condition; it is a seriously debilitating and progressive disease. Marked by stiffening of the oral mucosa and

development of fibrous bands, loss of elasticity of the mucosa results in a progressive restriction of mouth opening. Affected users experience a burning sensation of the oral mucosa, occasional mucosal ulceration, a peculiar marble-like blanching of the mucosa and palpable fibrous bands of the buccal mucosa, soft palate. Oesophageal subepithelial fibrosis, an extension of oral submucosal fibrosis, was seen more frequently in patients who had consumed pan masala, gutka, areca nut, tobacco or a combination of some or all of these, with or without betel leaf. Characteristics of Oral Submucous Fibrosis are palpable fibrous bands in buccal mucosa and soft palate, tough, leathery texture of the mucosa, blanching of the mucosa (defined as a persistent, white, marblelike appearance of the oral mucosa, which may be localized, diffuse or reticular), accompanied by histopathologic features characteristic of OSF (atrophic epithelium with loss of rete ridges and juxta-epithelial hyalinization of the lamina propria and the underlying muscle).<sup>6</sup>



**Fig 2-** Oral Submucous fibrosis with reduced mouth opening and blanching on palate and buccal mucosa

### Conclusion:

The oral mucosal lesion is generally influenced by the person's specific quid habits, and there seems to be a significant relationship between quid cessation and a decrease in the incidence rate of white lesions. No specific test is available to confirm whether a particular oral lesion was caused by the patient's quid habit. The diagnosis must be made on the basis of a history of repeated exposure to betel quid containing certain ingredients, the clinical appearance and the texture of the tissue. Incisional biopsy is recommended, specifically biopsy of the most severely affected area to rule out squamous cell carcinoma.

### References

1. Kaur J, Jain DC. Tobacco control policies in India: Implementation and challenges. *Indian J Public Health* 2011;55:220-7.
2. World Health Organization (WHO). WHO report on the global tobacco epidemic, Geneva, Switzerland: WHO; 2008.
3. Government of India, Ministry of health and family welfare, Global adult tobacco survey, India 2010.
4. Reddy SS, Prashanth R, Yashodha Devi B K, Chugh N, Kaur A, Thomas N. Prevalence of oral mucosal lesions among chewing tobacco users: A cross-sectional study. *Indian J Dent Res* 2015;26:537-41
5. Gupta PC, Ray CS. Smokeless tobacco and health in India and South Asia. *Respirology* 2003;8:419-31.
6. R. Sahitha , Effects of Smokeless Tobacco, Betel Quid and Areca Nut on Oral Mucosa , IOSR Volume 13, Issue 2 Ver. I. (Feb. 2014)
7. Antony George, et al, potentially malignant disorders of oral cavity, Vol 2. No 1. Jan- Jun 2011
8. Neville BW, Damm DD, Allen CM, Bouquot JE. Oral and maxillofacial pathology. 2nd ed. Philadelphia: W.B. Saunders Company;2002. p. 349-50.
9. Neville BW, Day TA. Oral cancer and precancerous lesions. *CA Cancer J Clin* 2002;52:195-215
10. van der Waal I. Potentially malignant disorders of the oral and oropharyngeal mucosa; terminology, classification and present concepts of management. *Oral Oncol* 2009;45:317-23.
11. Warnakulasuriya S, Johnson NW, Van DW. I. Nomenclature and classification of potentially malignant disorders of the oral mucosa. *J Oral Pathol Med* 2007;36:575-80.
12. Reichart PA, Philipsen HP. Oral erythroplakia: a review. *Oral Oncol* 2005;41:551-61.
13. Gandolfo S, Richiardi L, Carrozzo M, Broccoletti R, Carbone M, Pagano M, et al. Risk of oral squamous cell carcinoma in 402 patients with oral lichen planus: a follow-up study in an Italian population. *Oral Oncol* 2004;40:77-83.
14. Isaac van der Waal, Potentially malignant disorders of the oral and oropharyngeal mucosa; present concepts of management, *Oral Oncology* 46 (2010) 423-425

## Editorial Board



Dr. S C Bhoyar



Dr. Maya Mhaske



Dr. Nazish Baig




Dr. Sanjay Sarode



Dr. Niraj Chaudhari



Dr. Anup Cholepatil



Dr. Aniruddha Deshpande



Dr. Jayant Ambulgekar



Dr. Ashok Chatse

## CSMSS DENTAL COLLEGE & HOSPITAL, KANCHANWADI, AURANGABAD

